



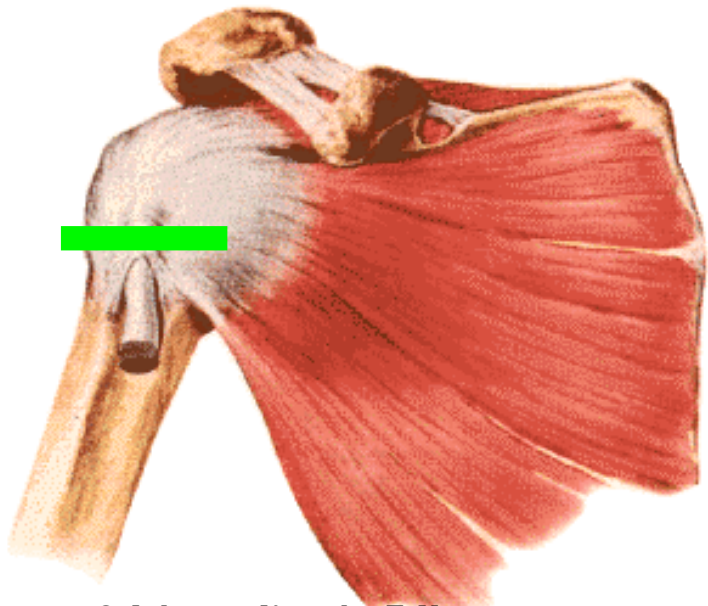
Echographie de l'épaule

A. Silvestre



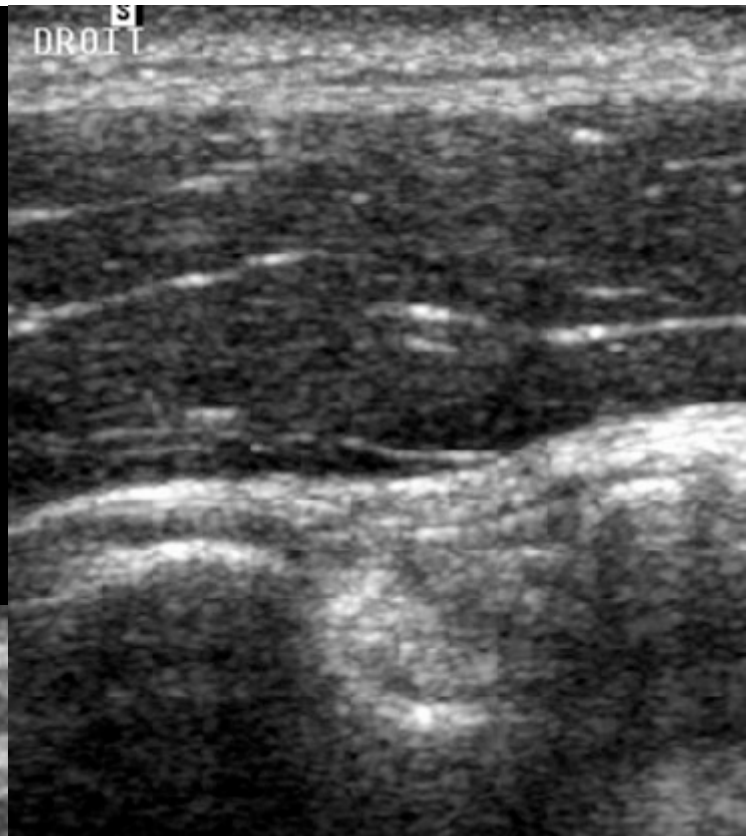Echo anatomie normale



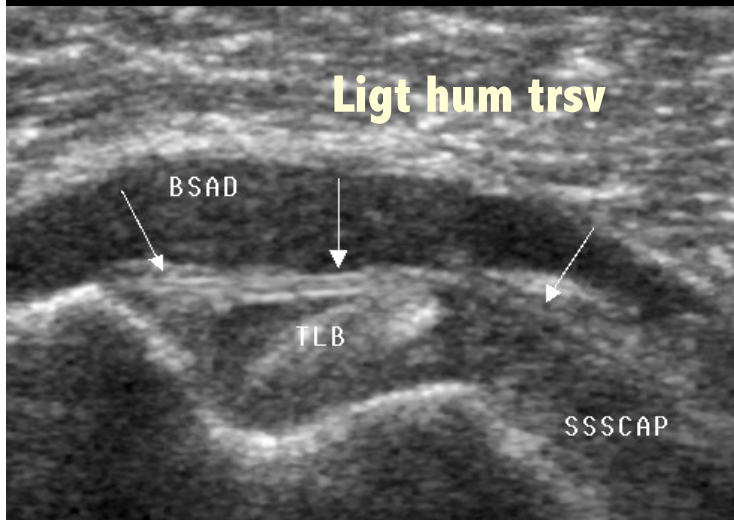


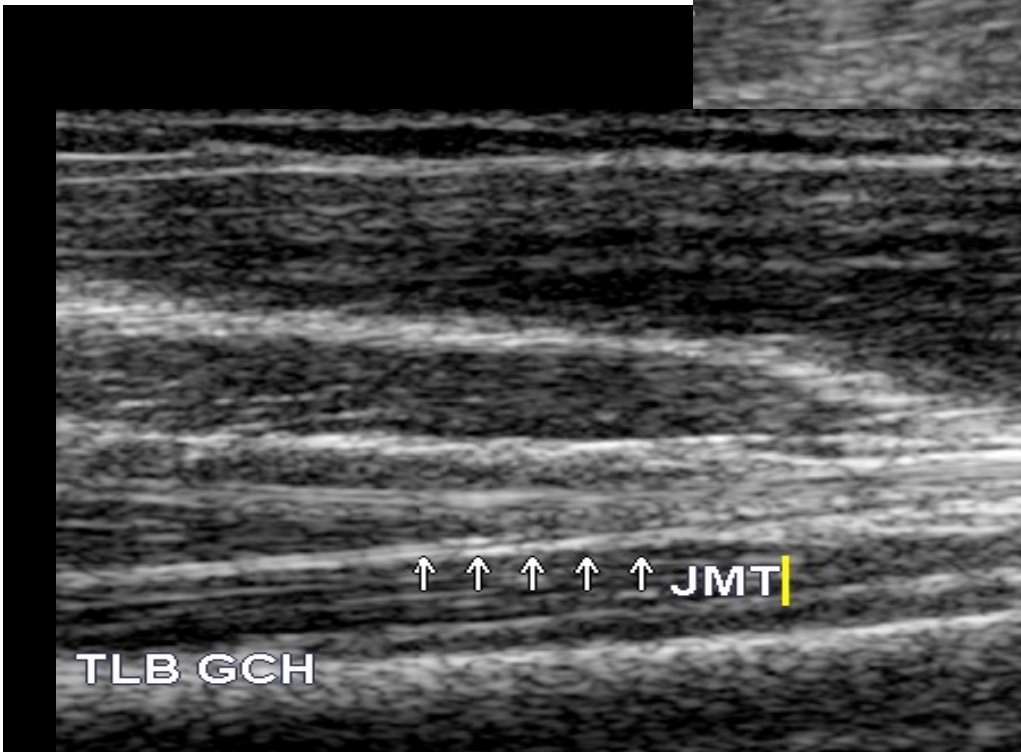
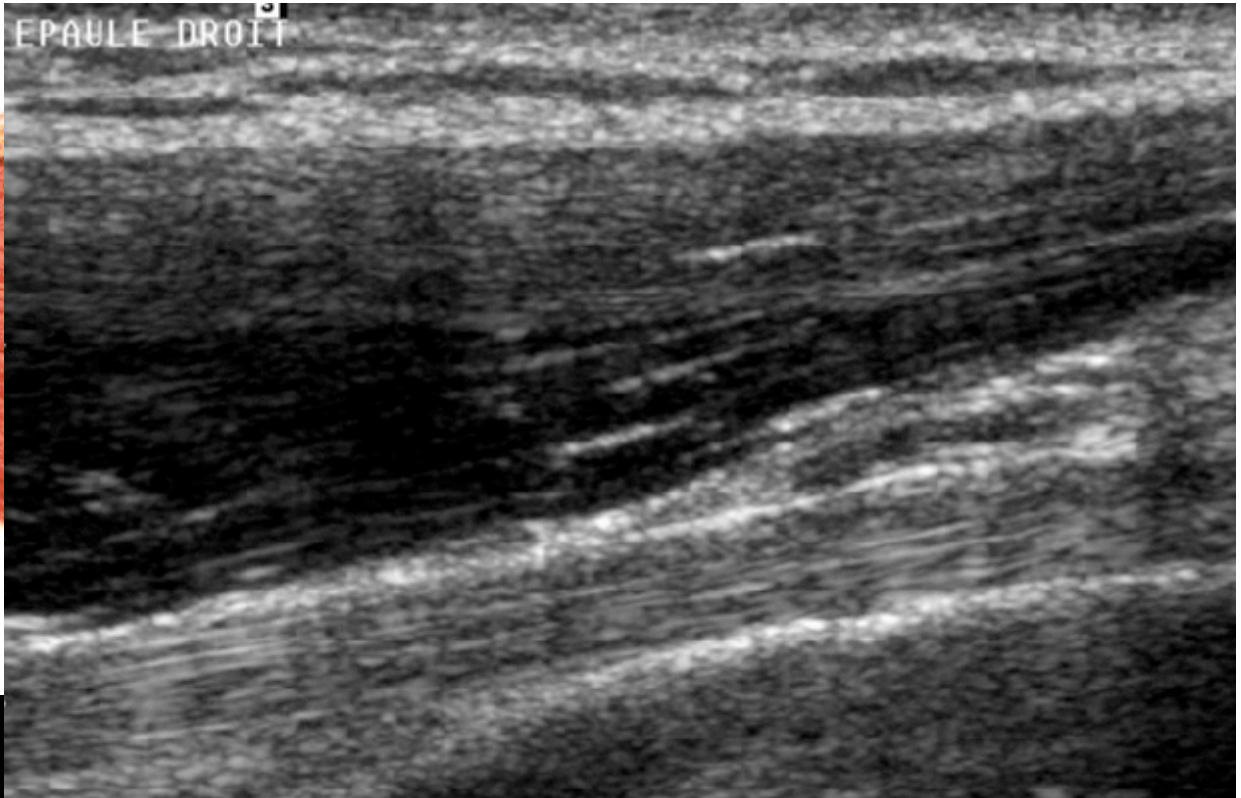
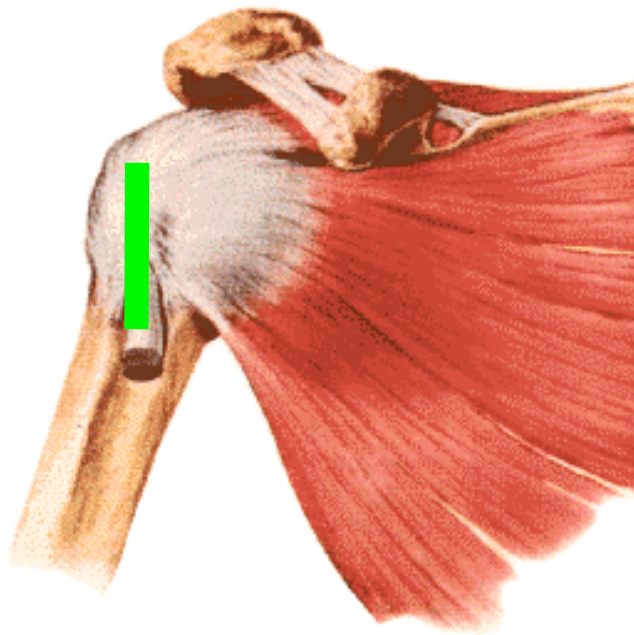
Schémas d'après F.Netter

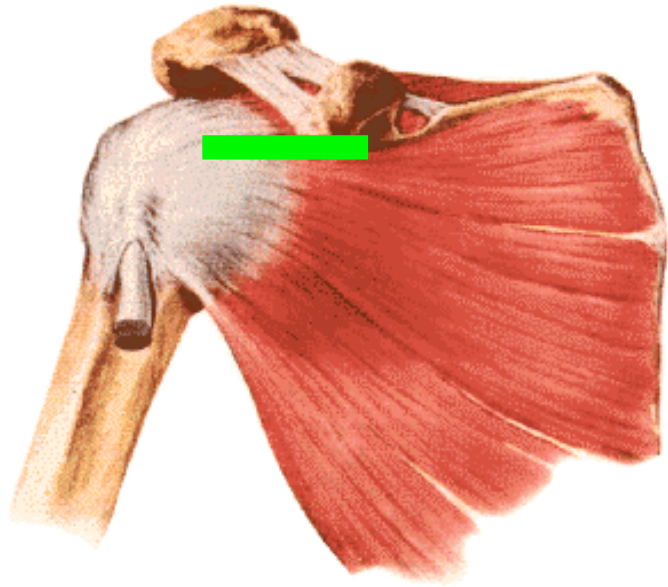
TLB



Ligt hum trsv

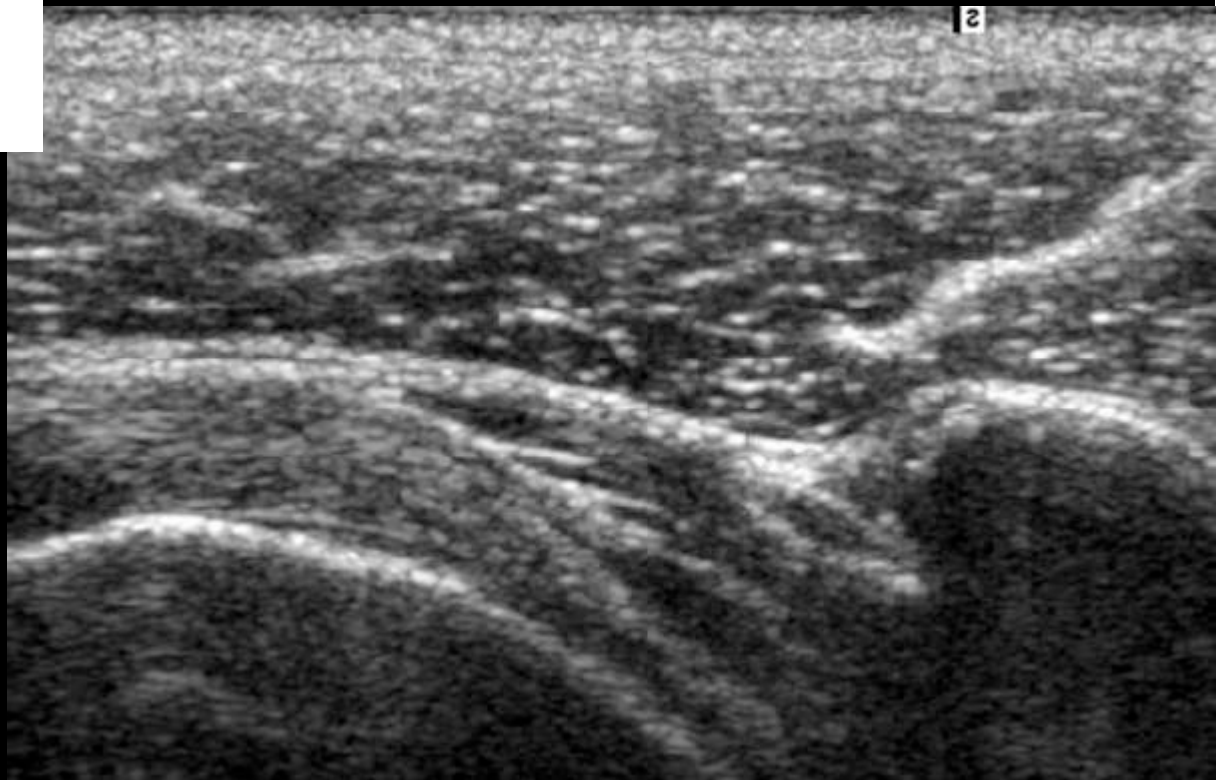

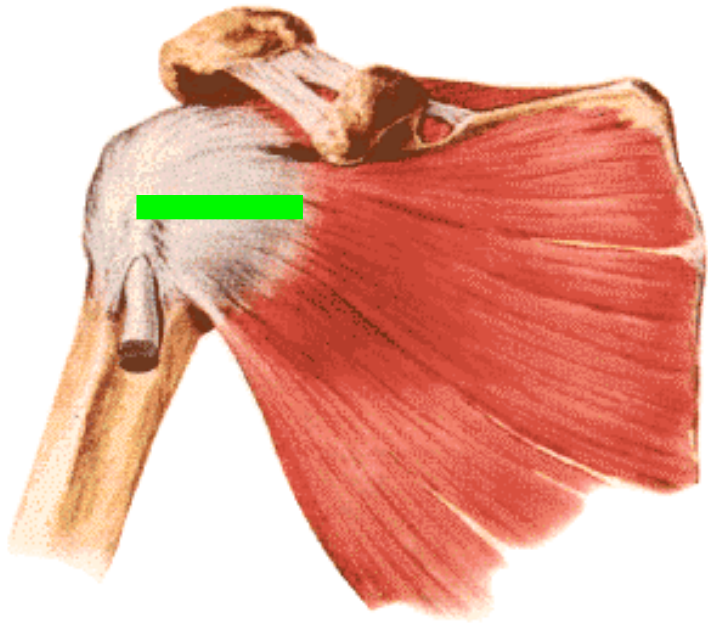




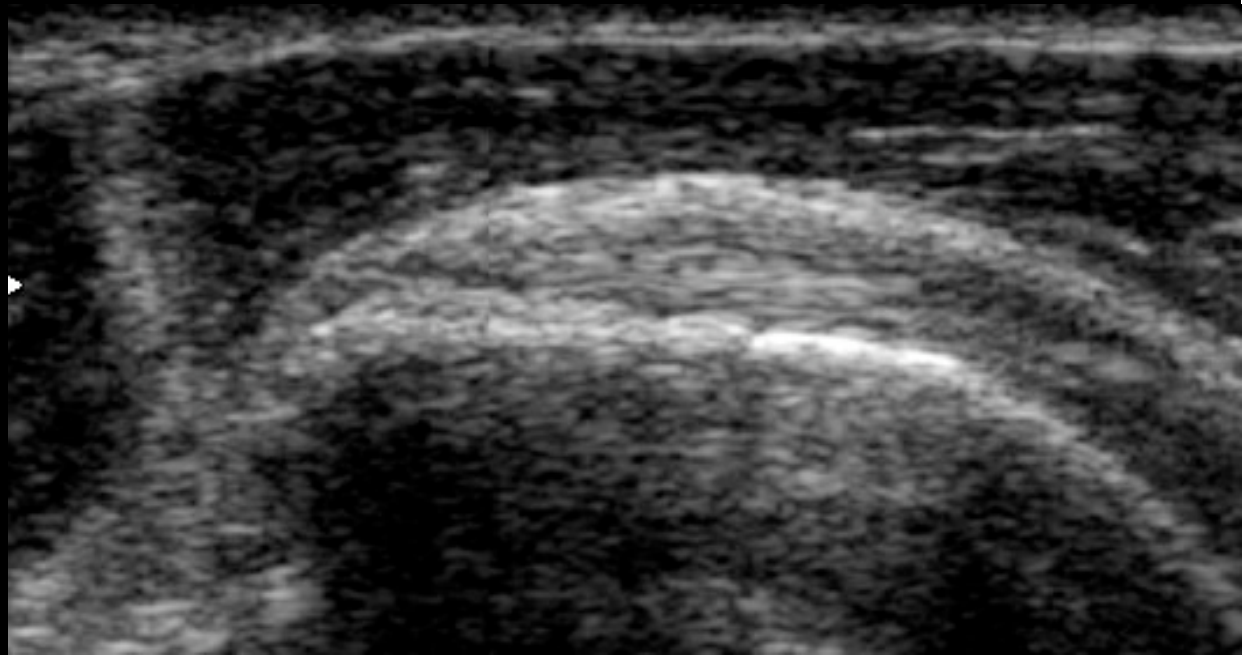
SUB SCAPULAIRE

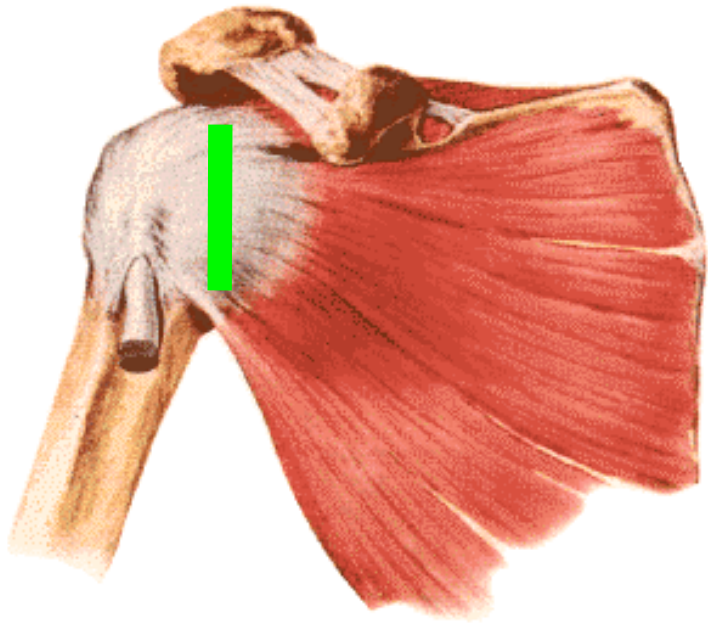
Jonction myo tendineuse



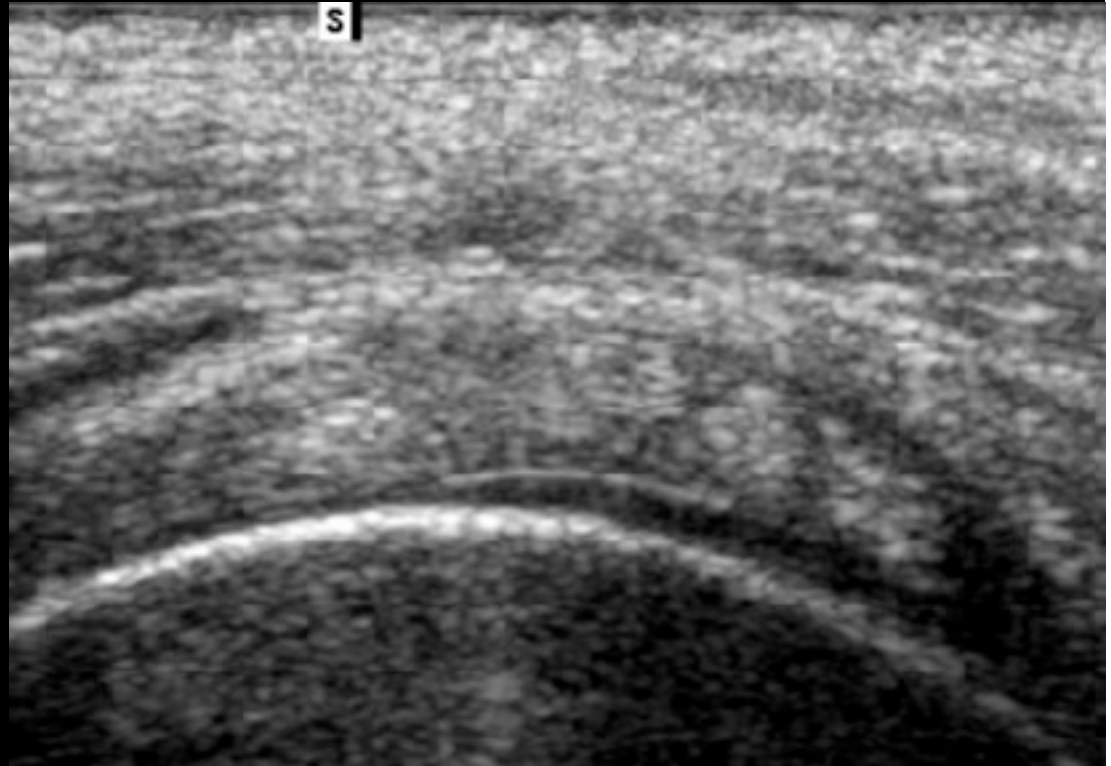


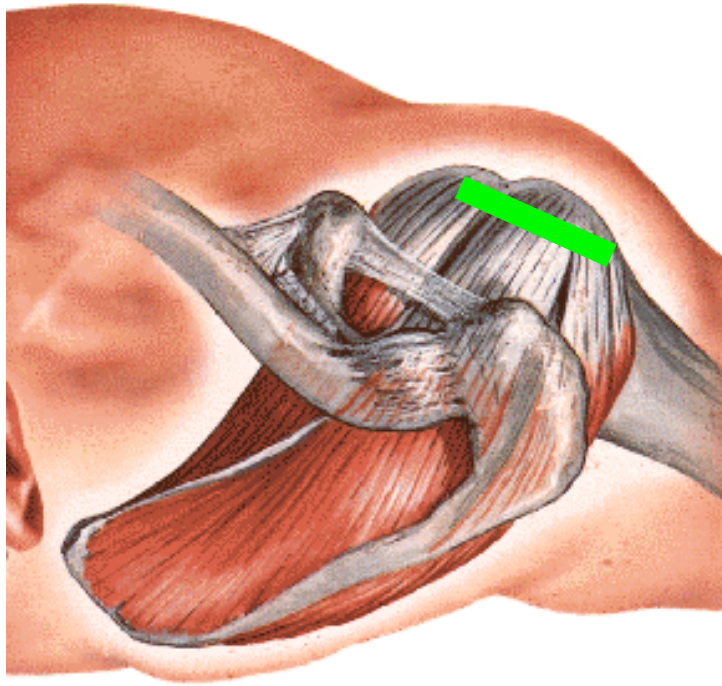
SUB SCAPULAIRE enthèse





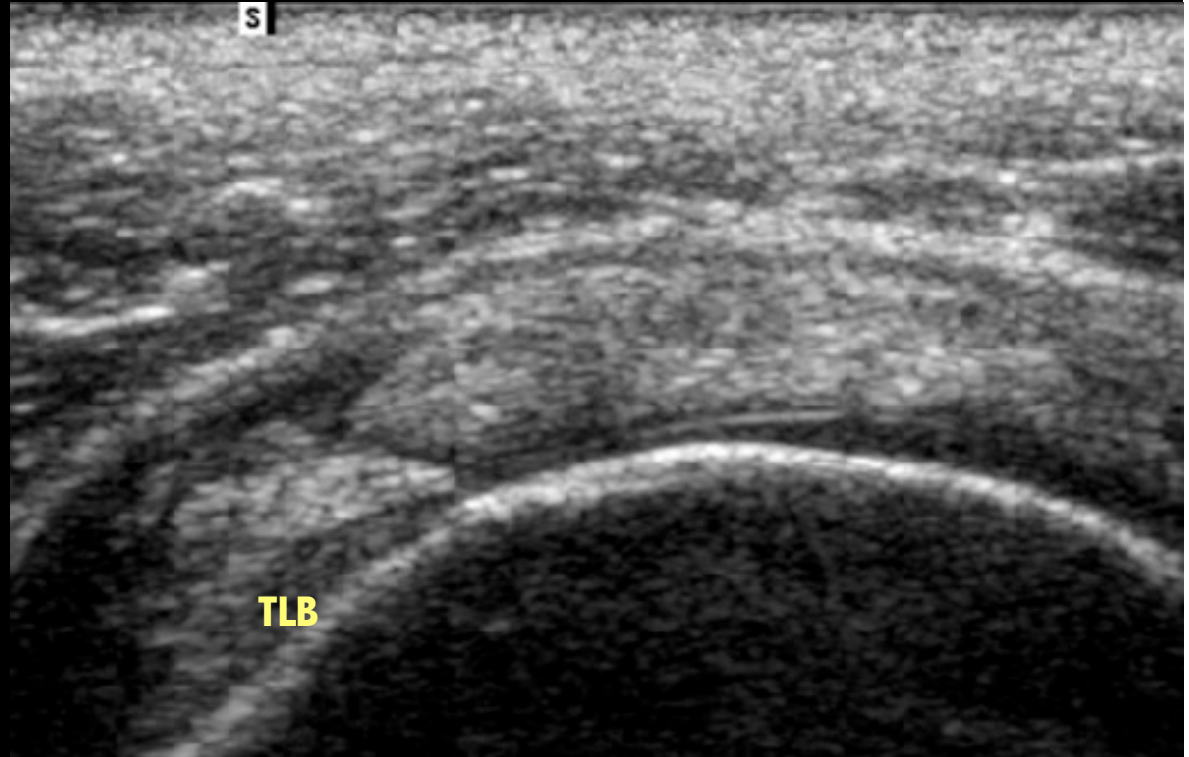
SUB SCAPULAIRE

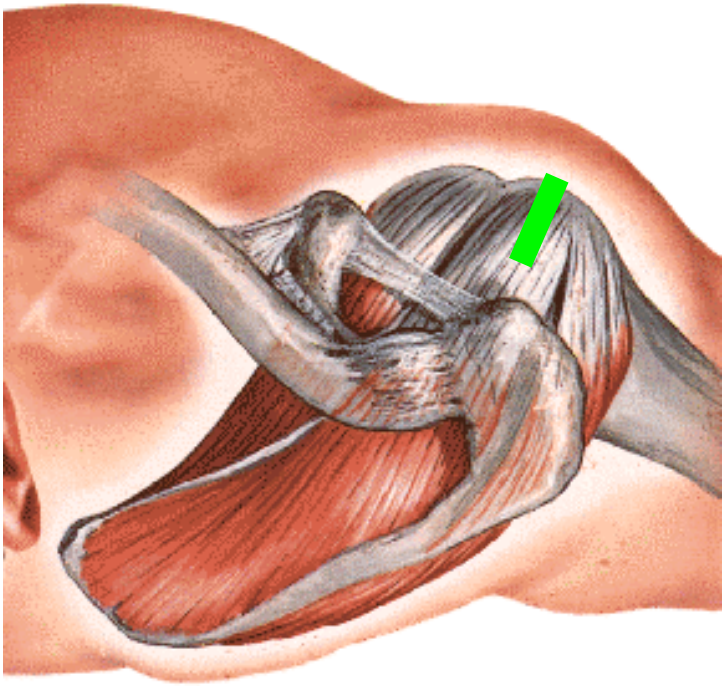




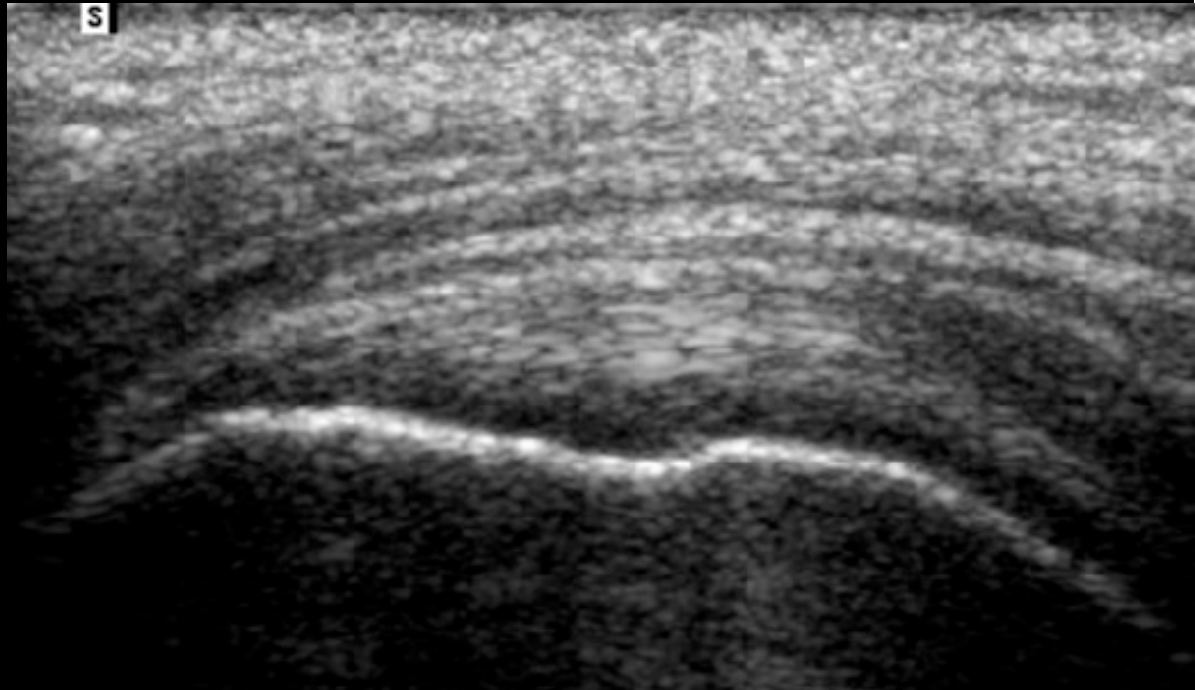
SUPRA EPINEUX

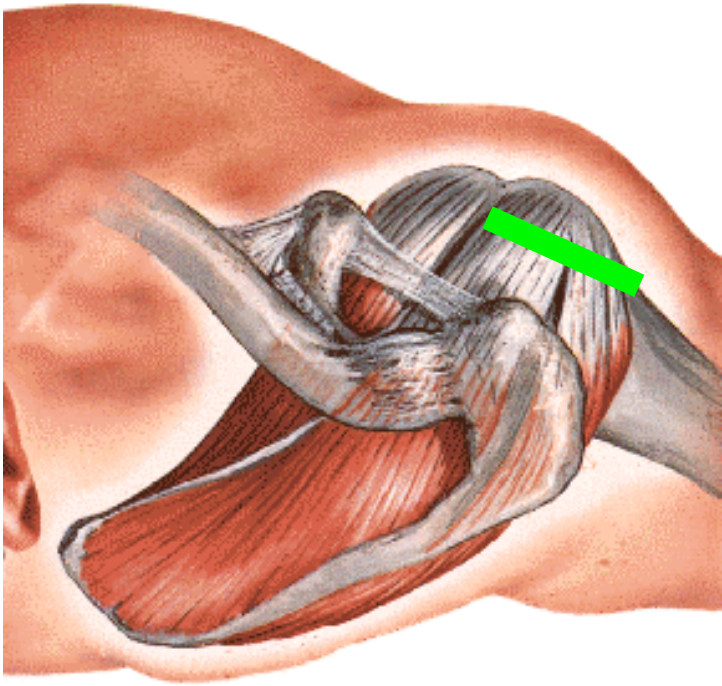
Partie antérieure



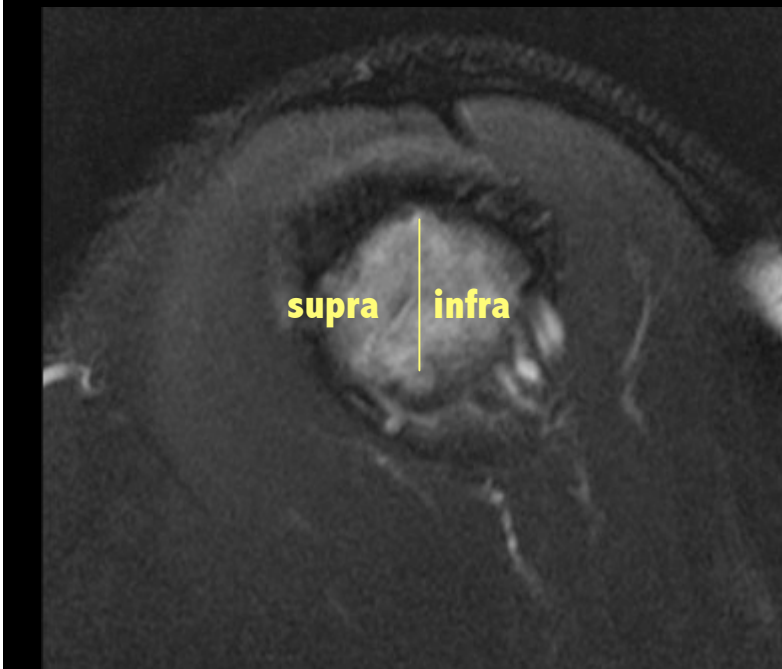
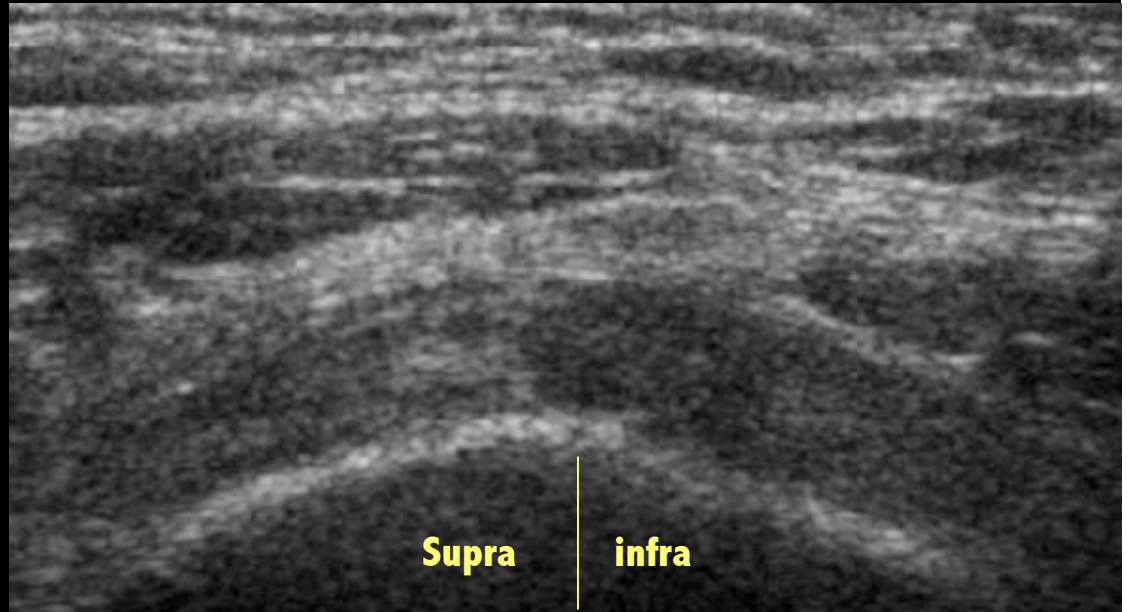


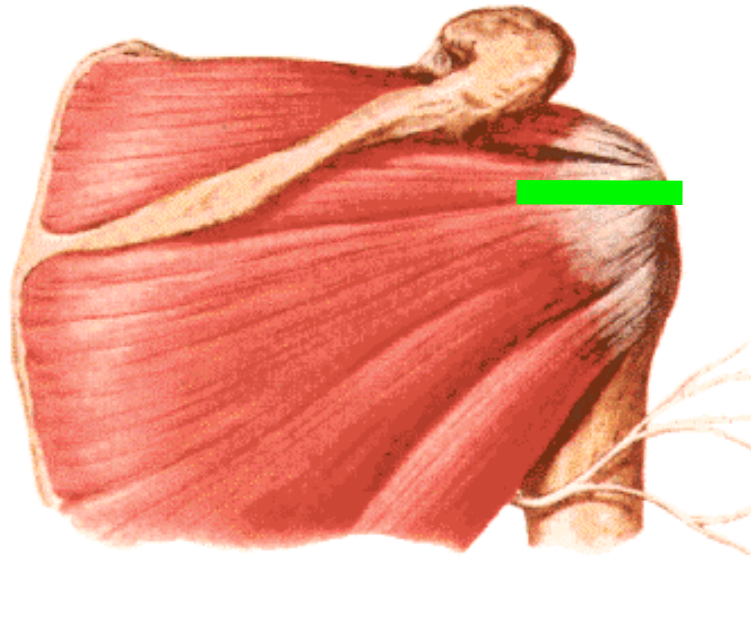
SUPRA EPINEUX





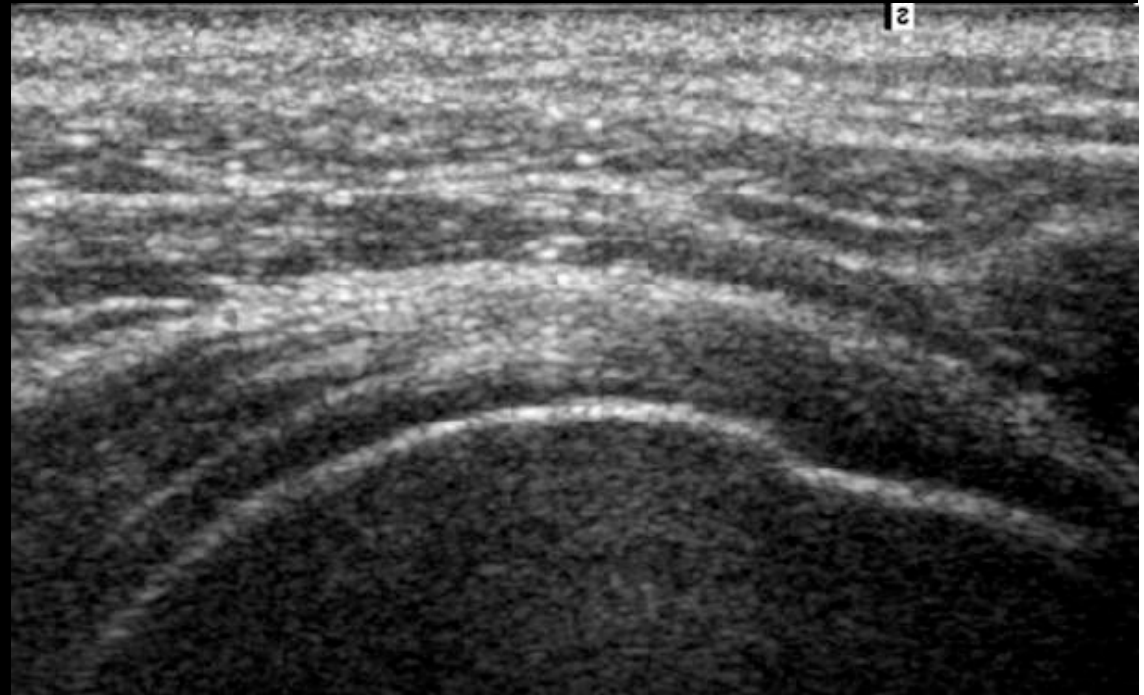
SUPRA EPINEUX/ INFRA EPINEUX

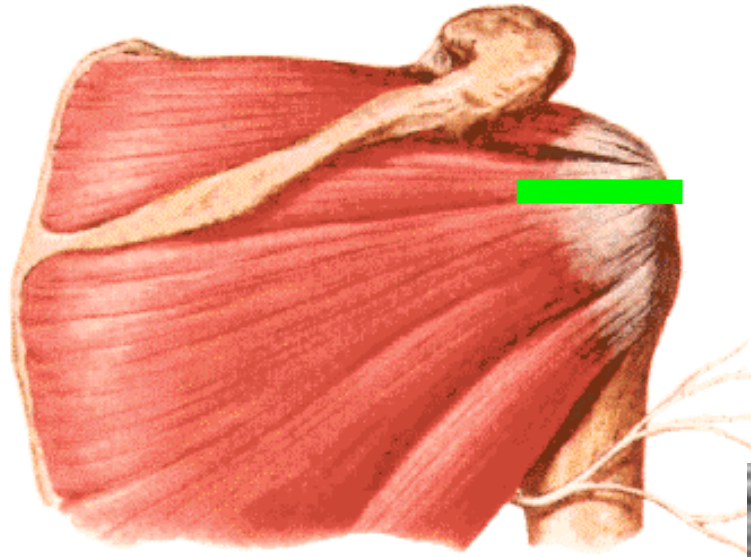




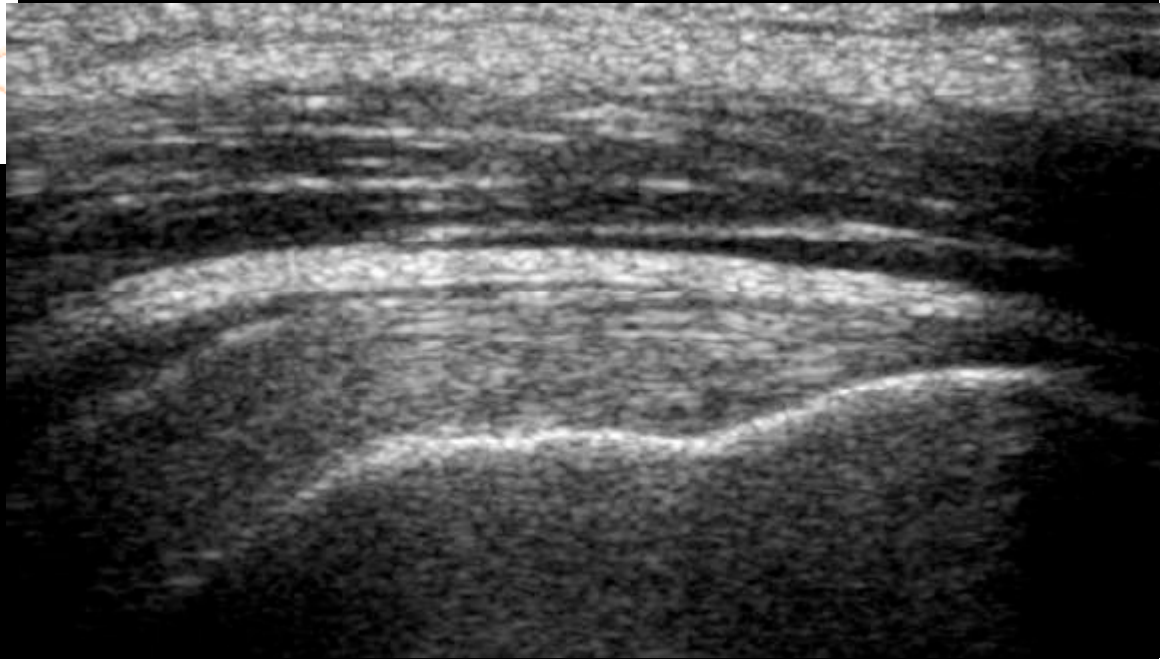
INFRA EPINEUX

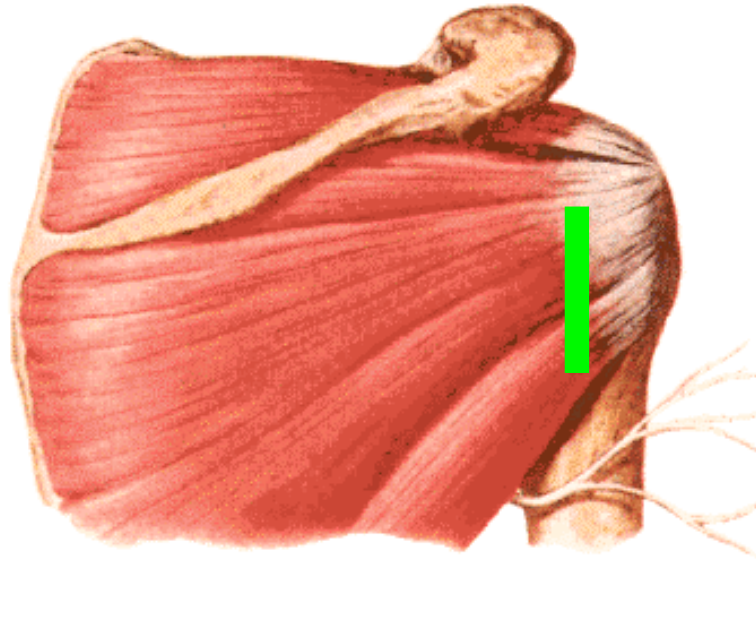
Jonction myo tendineuse



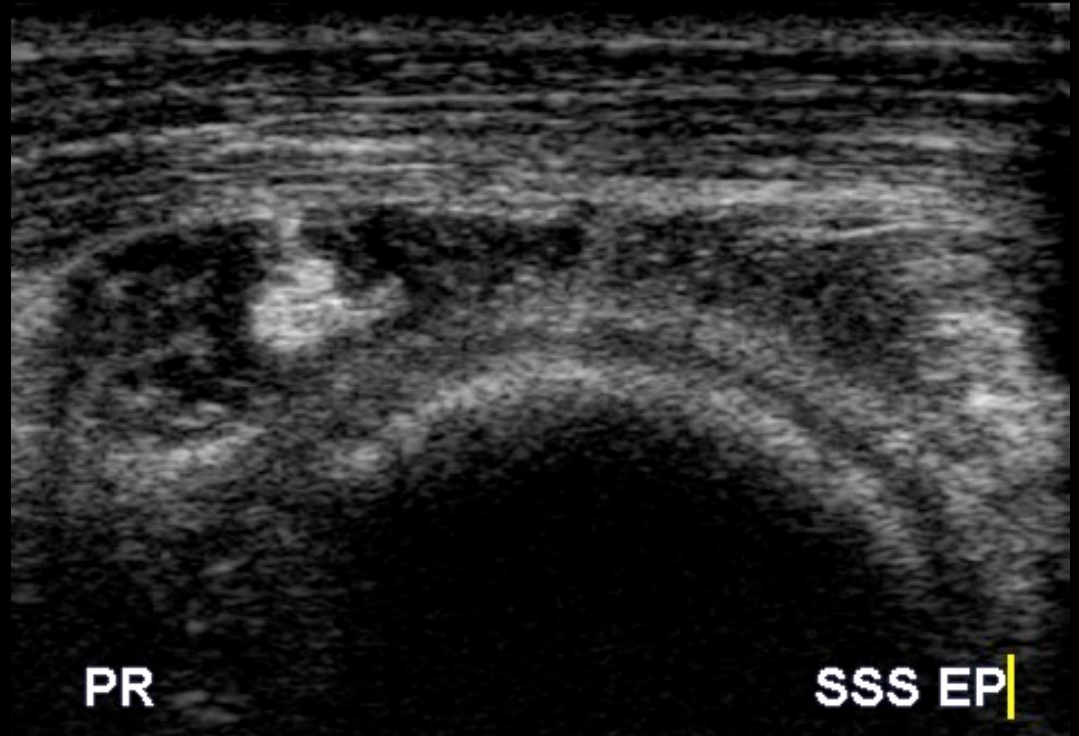


INFRA EPINEUX enthèse



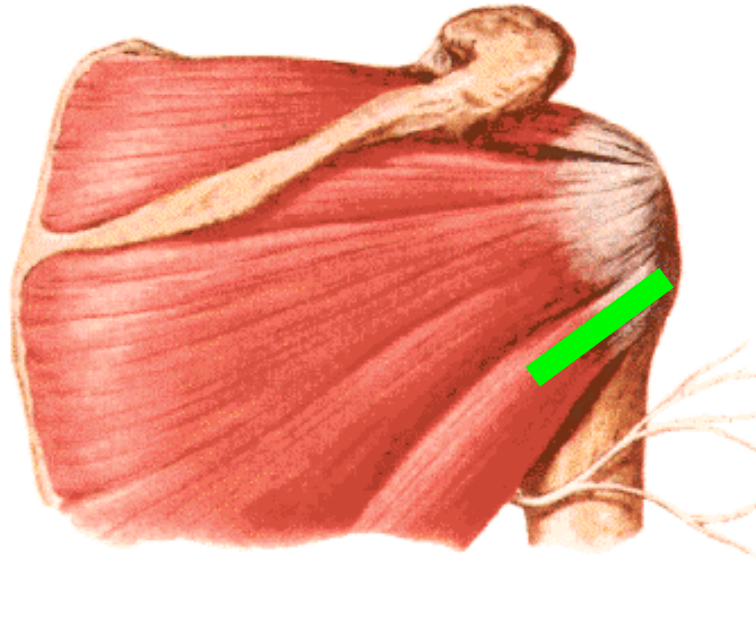


PETIT ROND

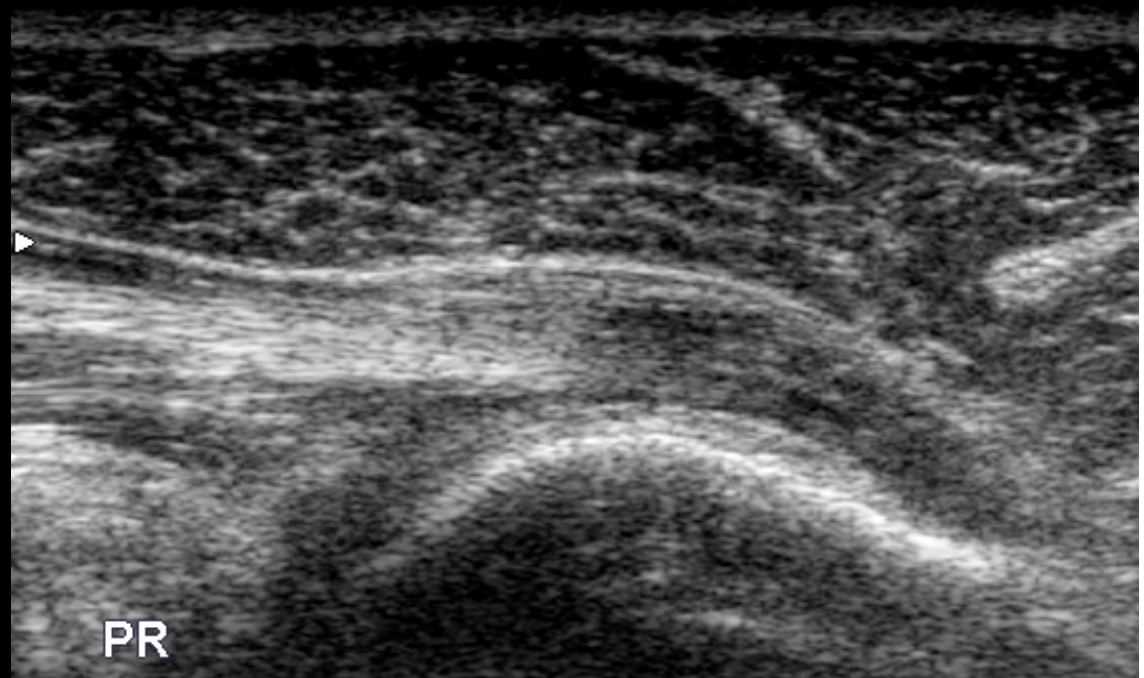


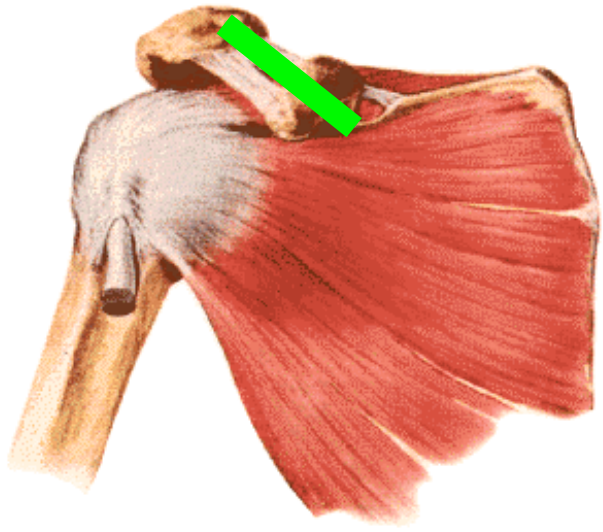
PR

SSS EP



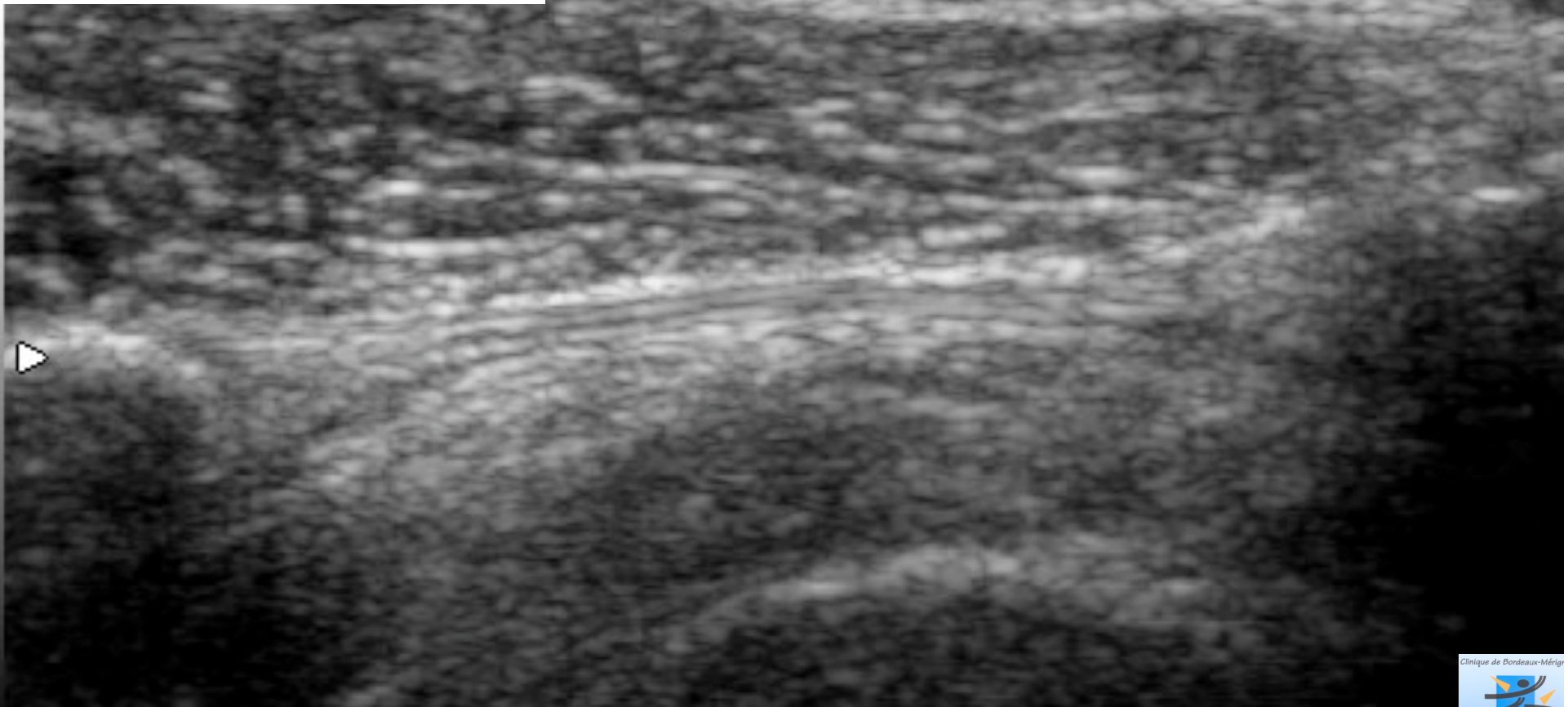
PETIT ROND

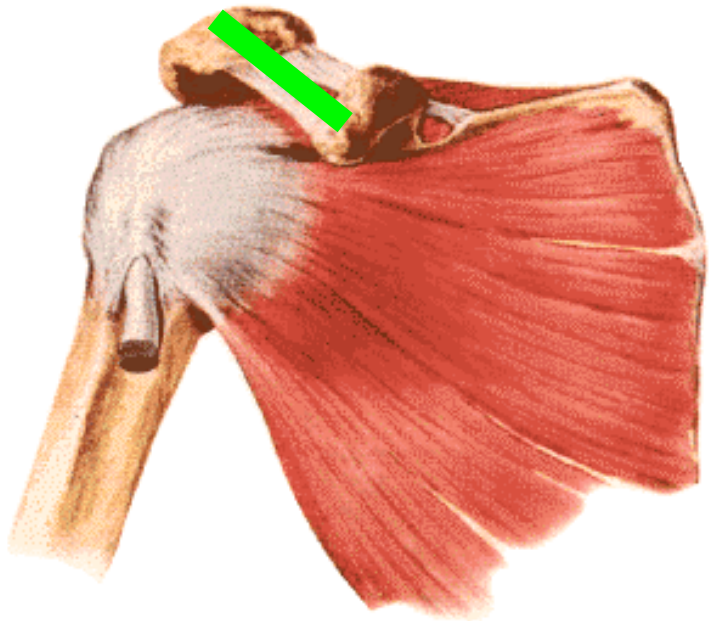




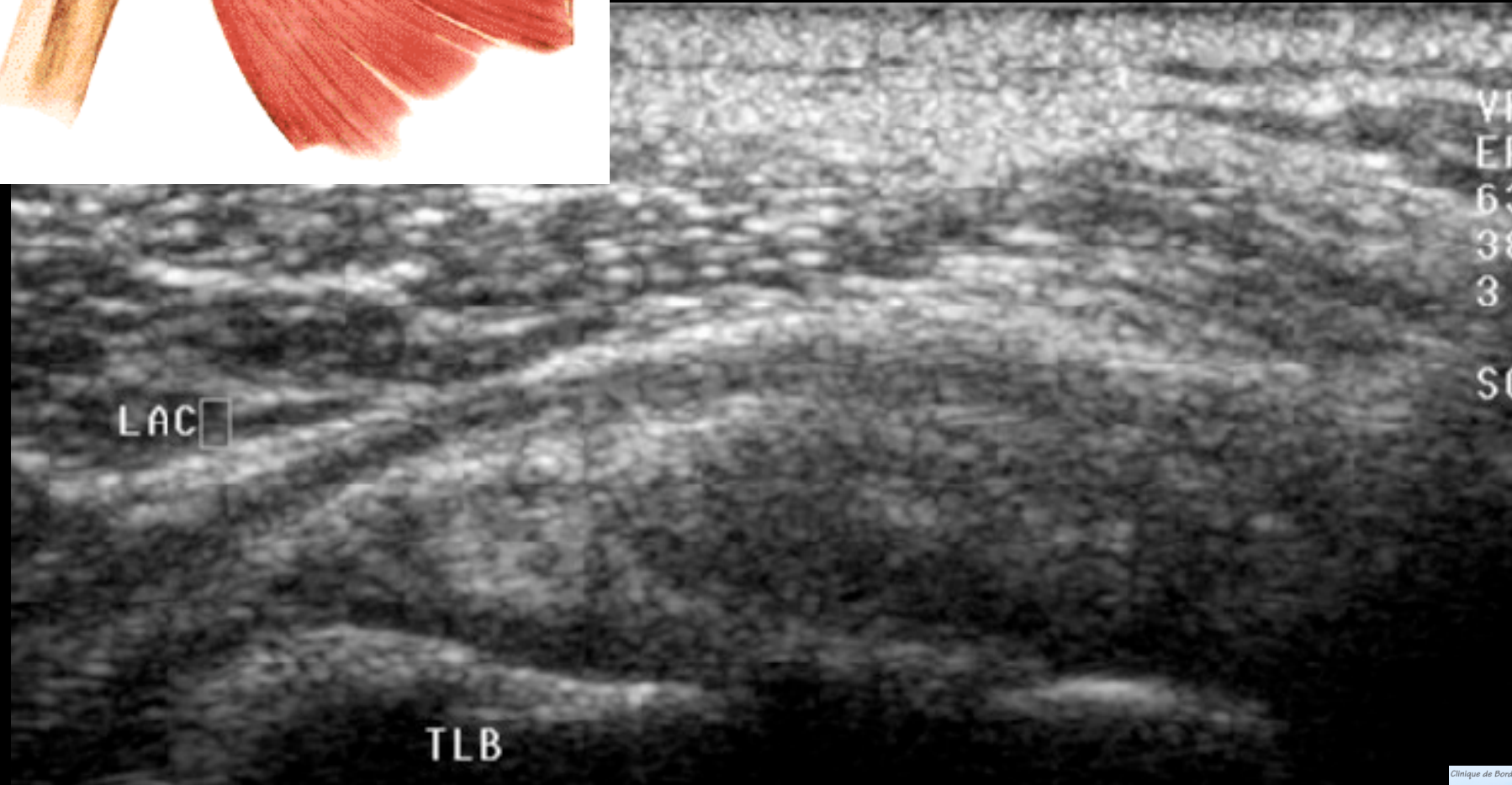
LAC

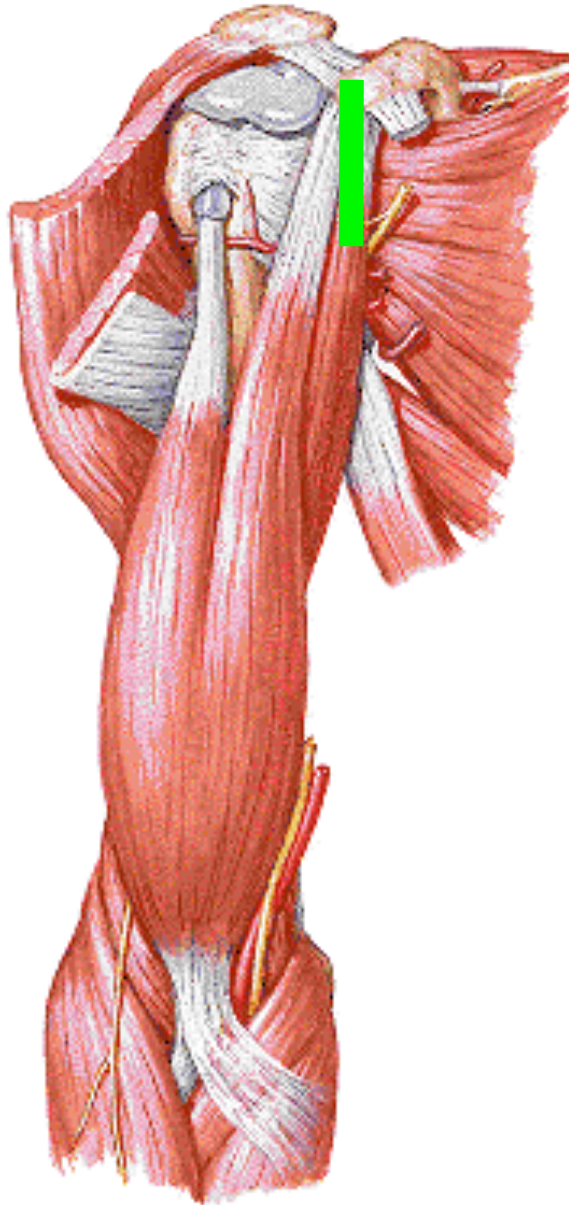
000



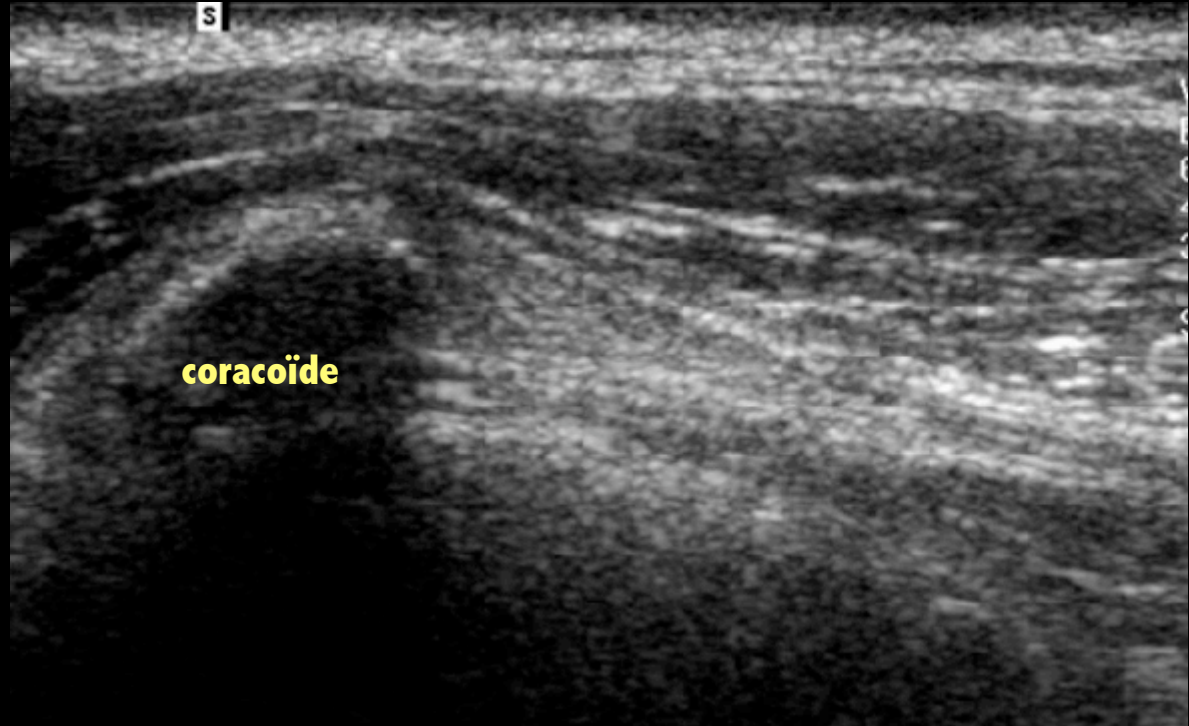


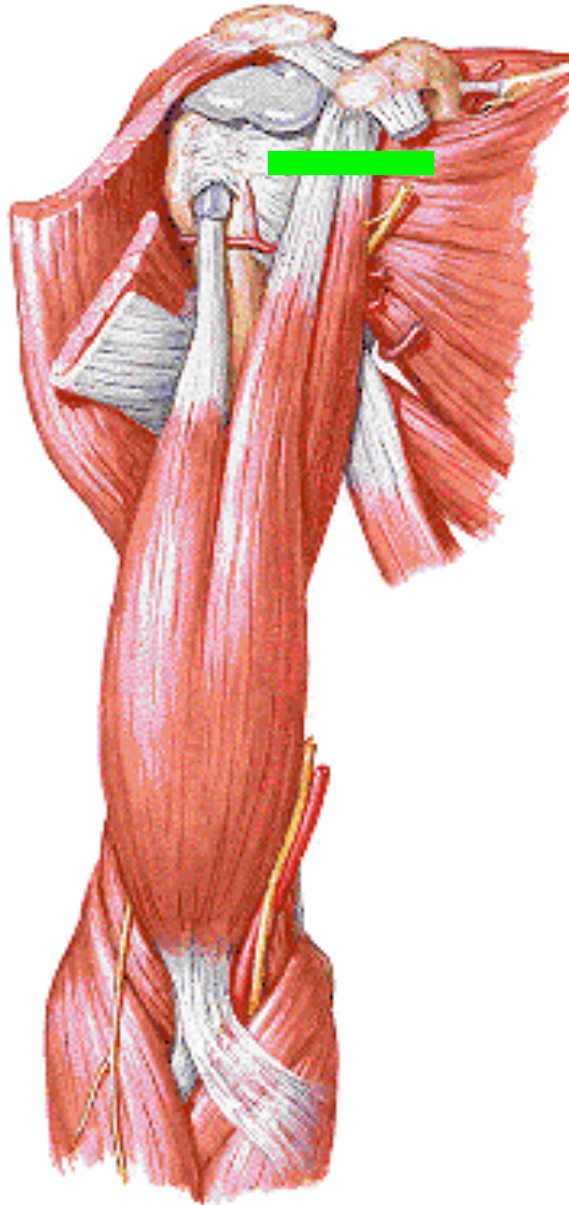
LAC



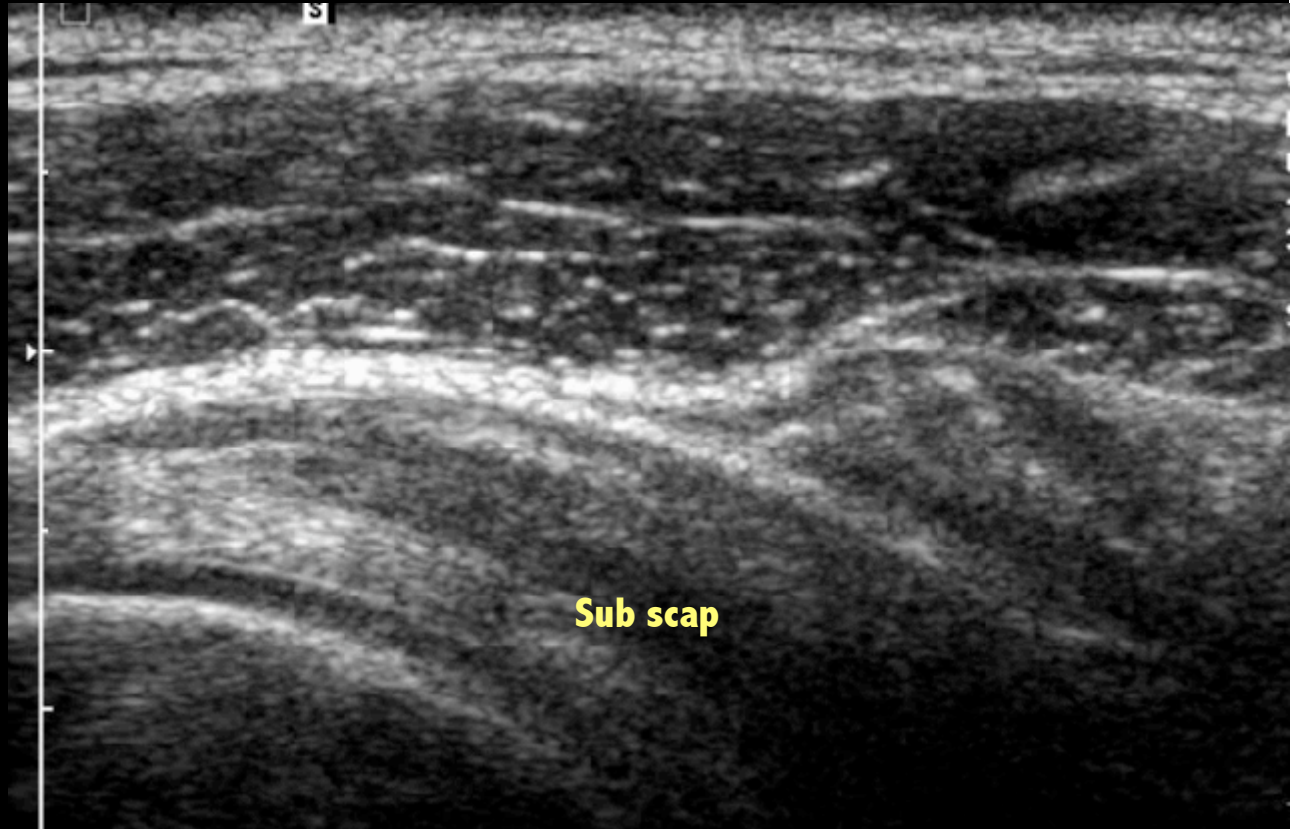

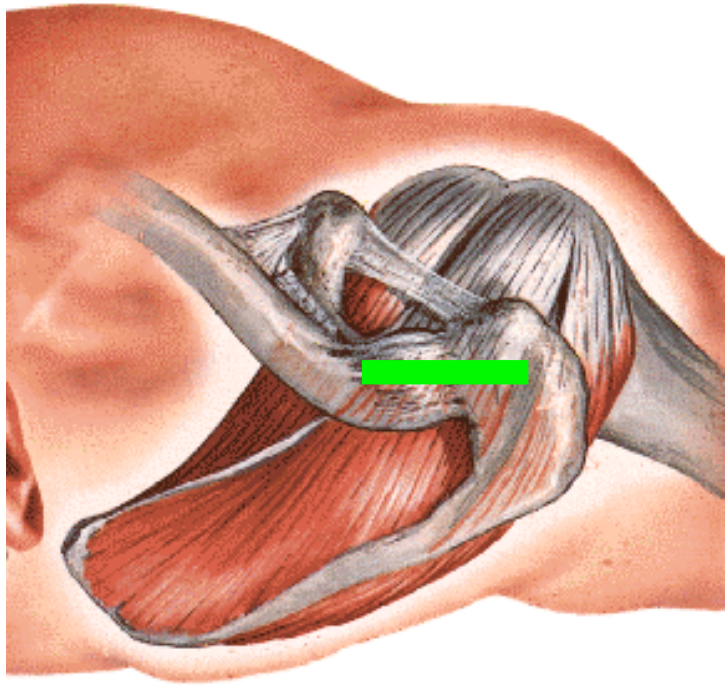
CORACO BICEPS & CORACO BRACHIAL



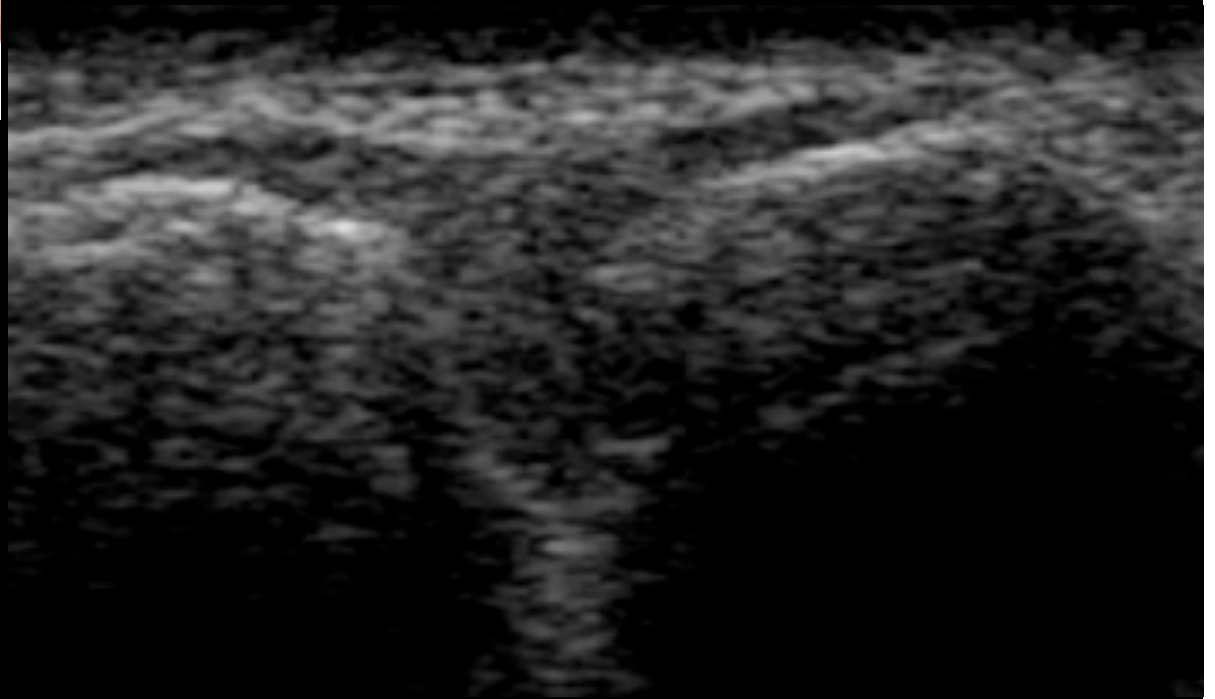


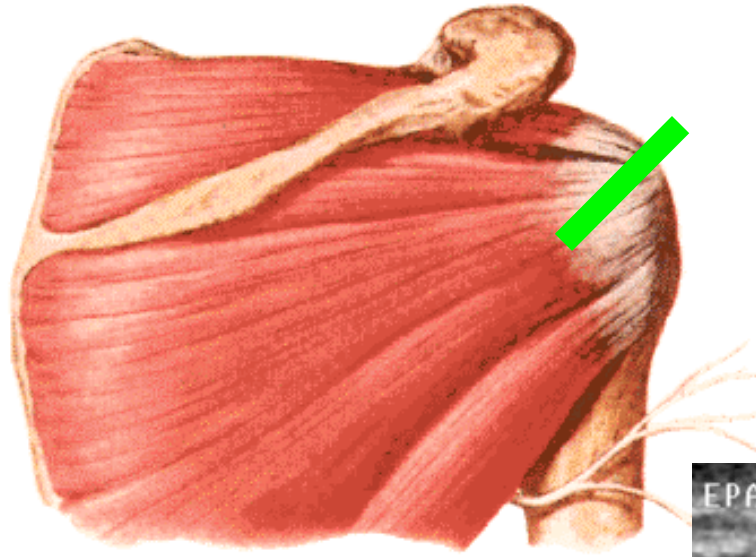
CORACO BICEPS & CORACO BRACHIAL



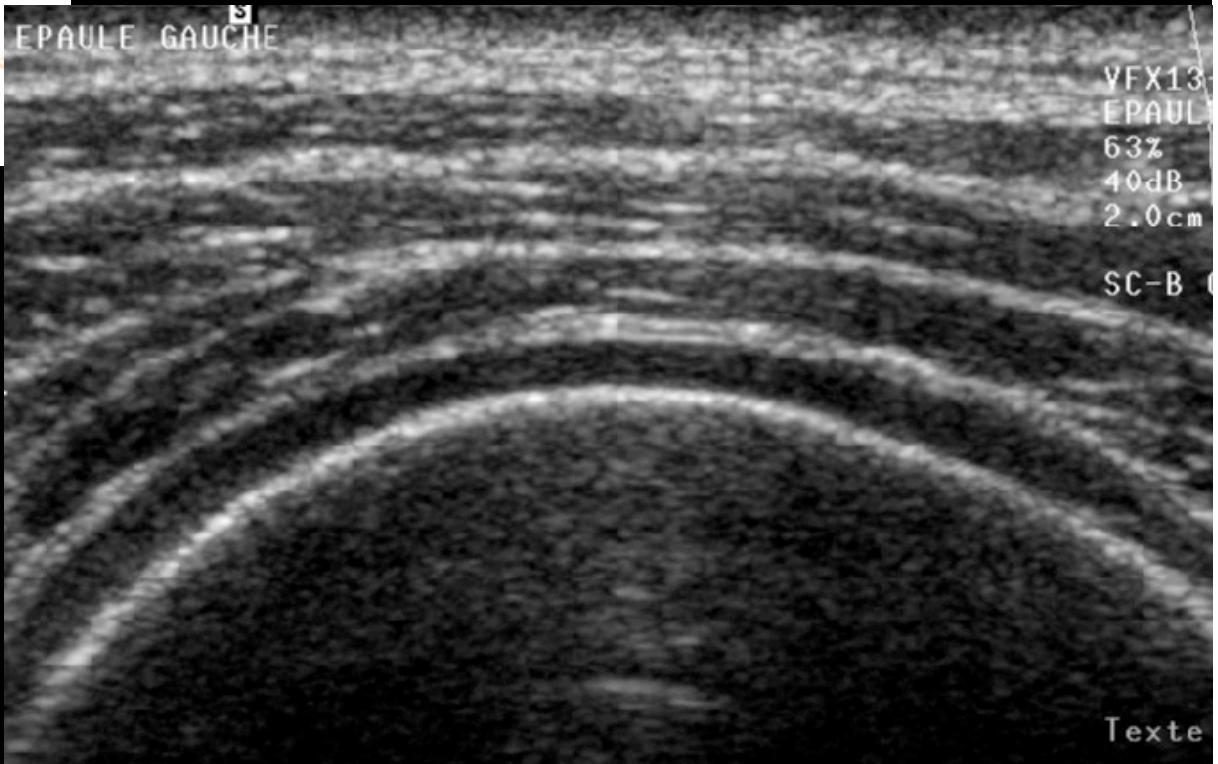


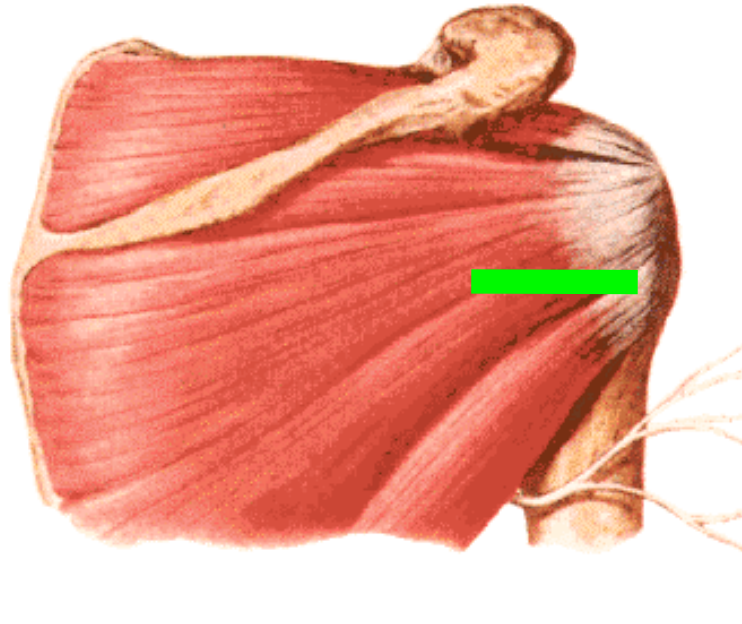
A° ACROMIO CLAV





CARTILAGE TETE

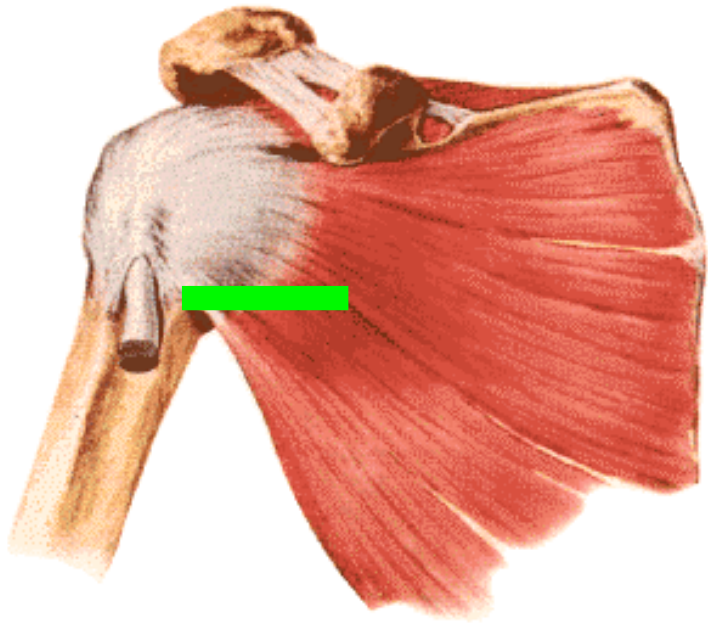




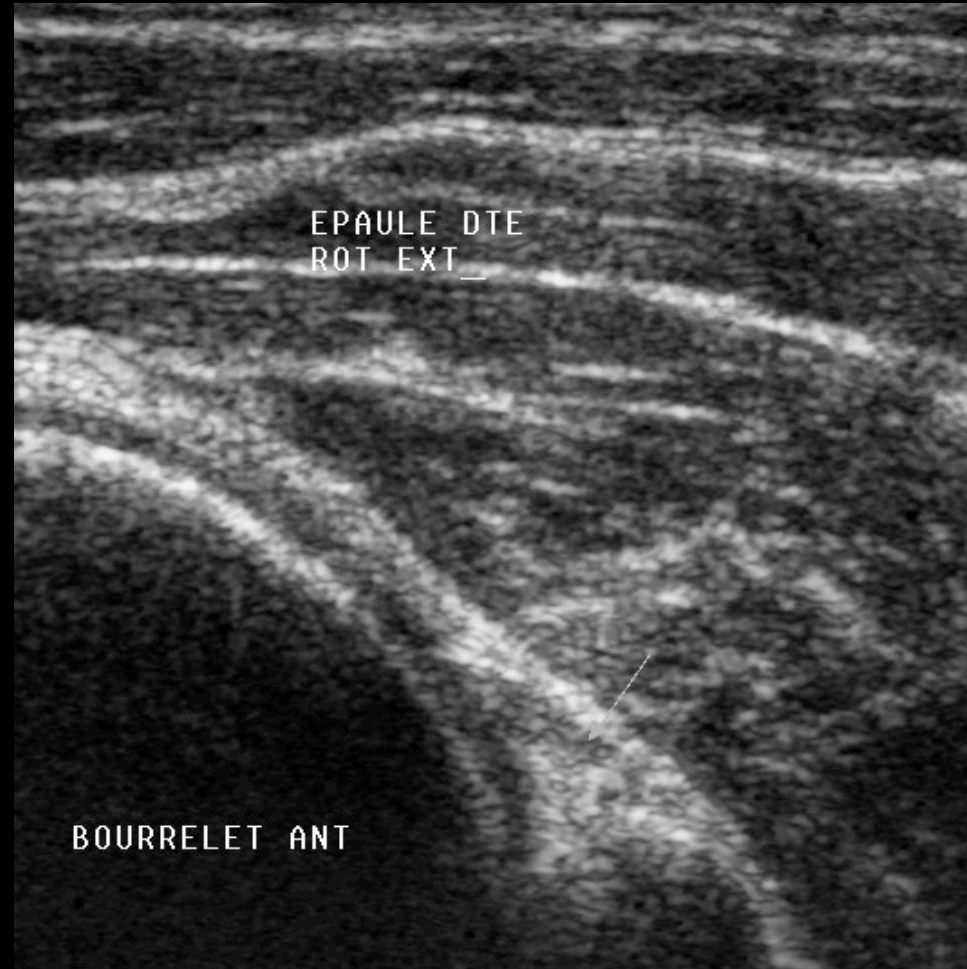
LABRUM POST

000

LABRUM POST



LABRUM ANT



INSERTION DELTOÏDE

