

ROLE OF ULTRASOUND IN THE EVALUATION OF SCAPHOLUNATE LIGAMENT TEARS: A PICTORIAL REVIEW



**Centre d'imagerie ostéo-articulaire
Clinique du sport de Mérignac**

Lionel PESQUER (1), Philippe PELISSIER (2) , Philippe MEYER (1)

(1) MD - Centre d'Imagerie Ostéo-articulaire - Clinique du Sport de Bordeaux - Mérignac - France

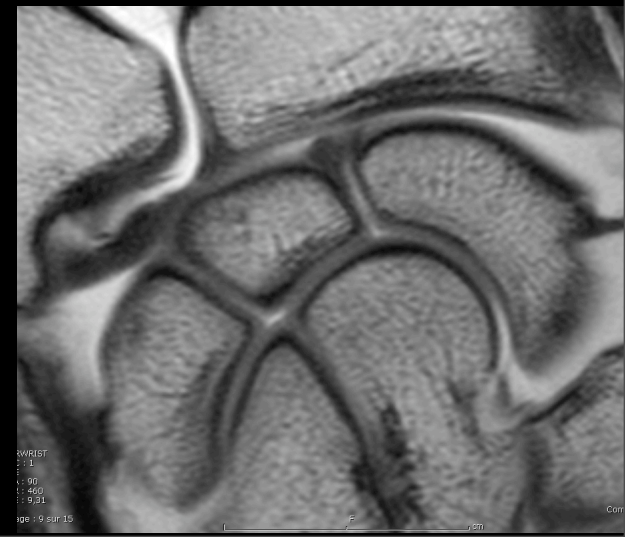(2) PhD- Service de Chirurgie de la main - CHU de Bordeaux - France

Learning objectives

1. To review the normal anatomy
2. To know how to explore Scapholunate ligament with US
3. To describe the US aspects of scapholunate injuries
4. To discuss the strengths and weaknesses of US examination

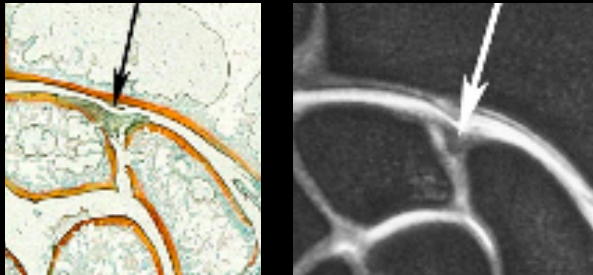
Plan

1. Introduction
2. Backgrounds: Anatomy & pathology
3. Pictorial review
 - Normal US aspects of scapholunate ligament
 - US patterns of scapholunate ligament injuries
 - Differential diagnosis
4. Discussion
5. Conclusion



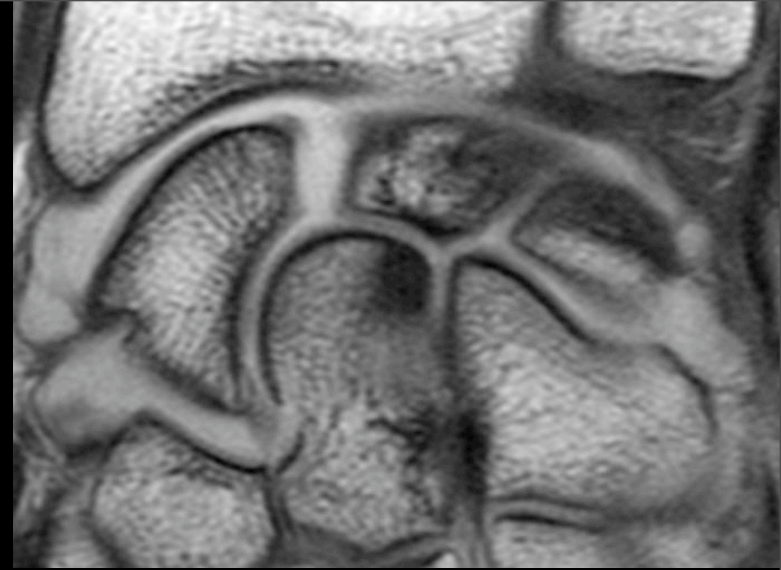
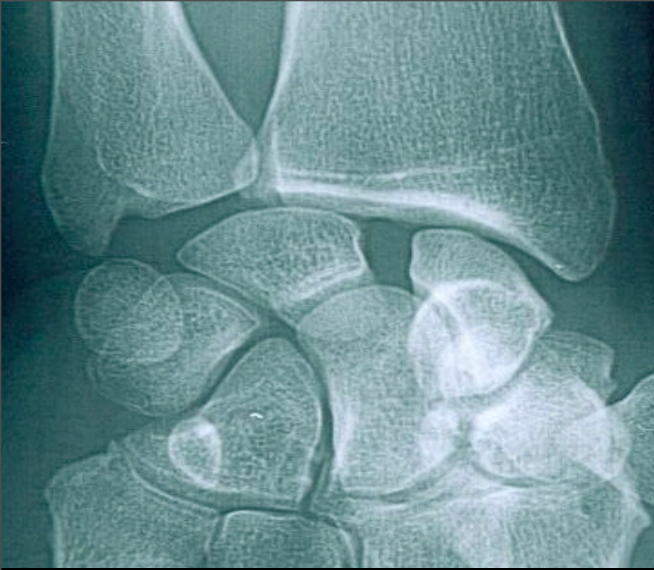INTRODUCTION

- Scapholunate ligament is one of the major actors in wrist stability especially in one of the proximal carpal raw bones.

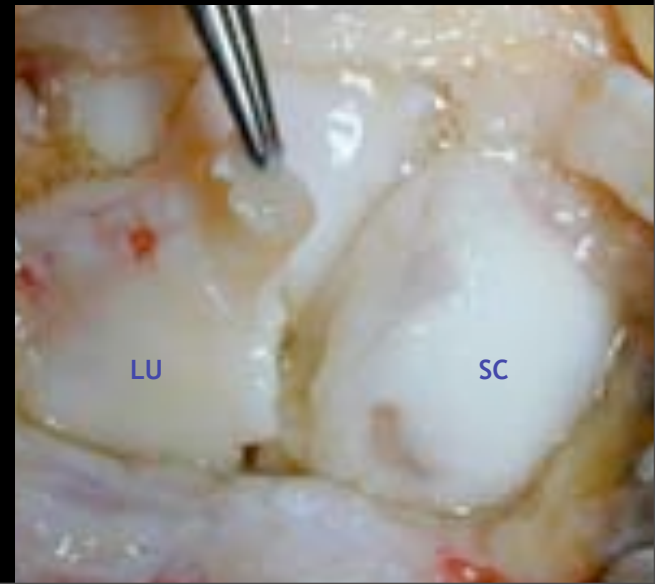
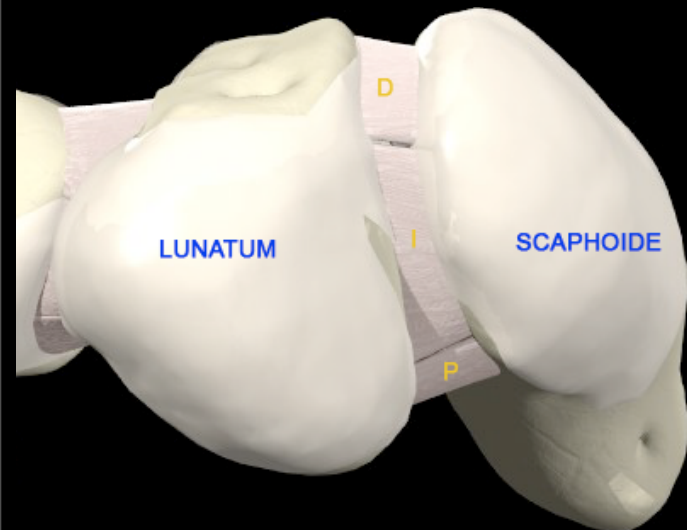


Zlatkin MB, Rosner J. MR Imaging of ligaments and triangular fibrocartilage complex of the wrist. J Magn Reson Imaging Clin N Am 2004; 12:301-333

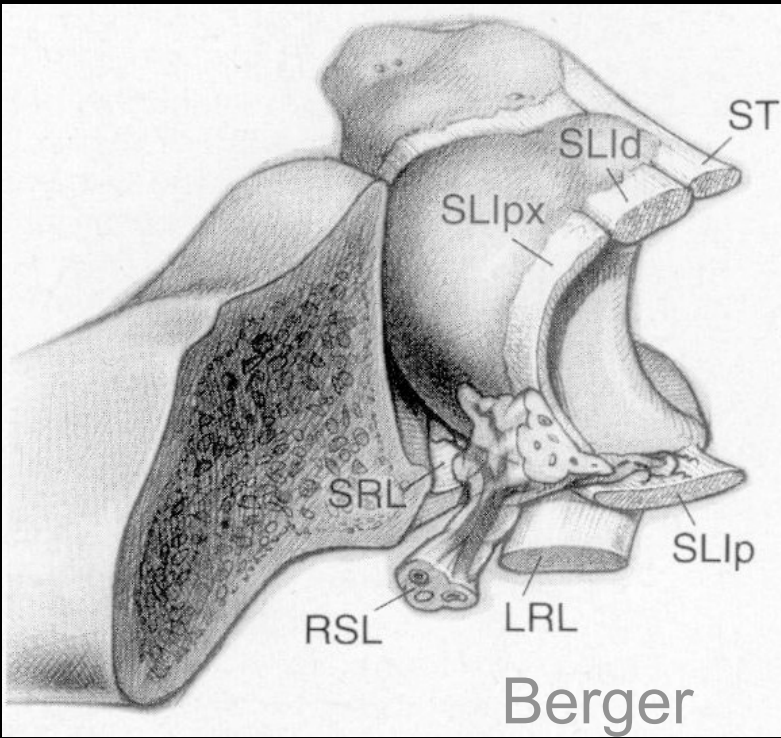
- Scapholunate instability is the most common type of carpal instability and remains a diagnostic problem clinically and radiologically. It has a poor prognosis when insufficiently diagnosed and treated.
- Indeed, unknown lesions can lead to quick and severe instability and cause multiple chondral lesions.
- Its analysis is currently done by Arthro-Ct, Arthro-MRI or MRI. The use of a low-cost, non-invasive, accurate and widely available imaging method such as ultrasonography has obvious benefits.
- Our purpose is to describe the normal and pathologic aspects of scapholunate ligament at ultrasonography.



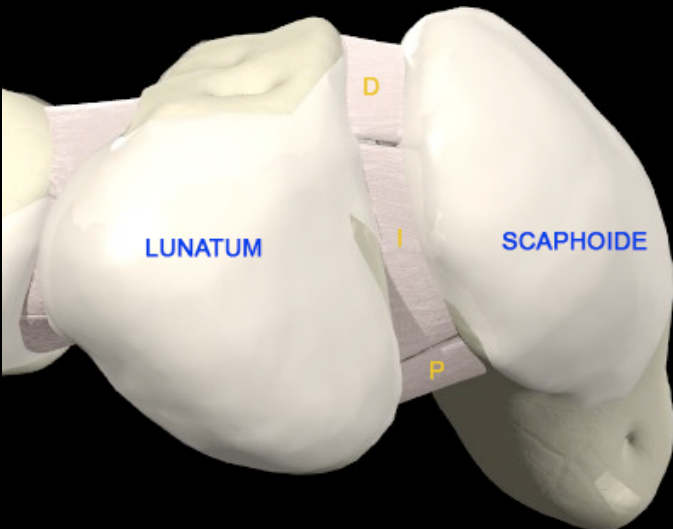
BACKGROUNDS



ANATOMY

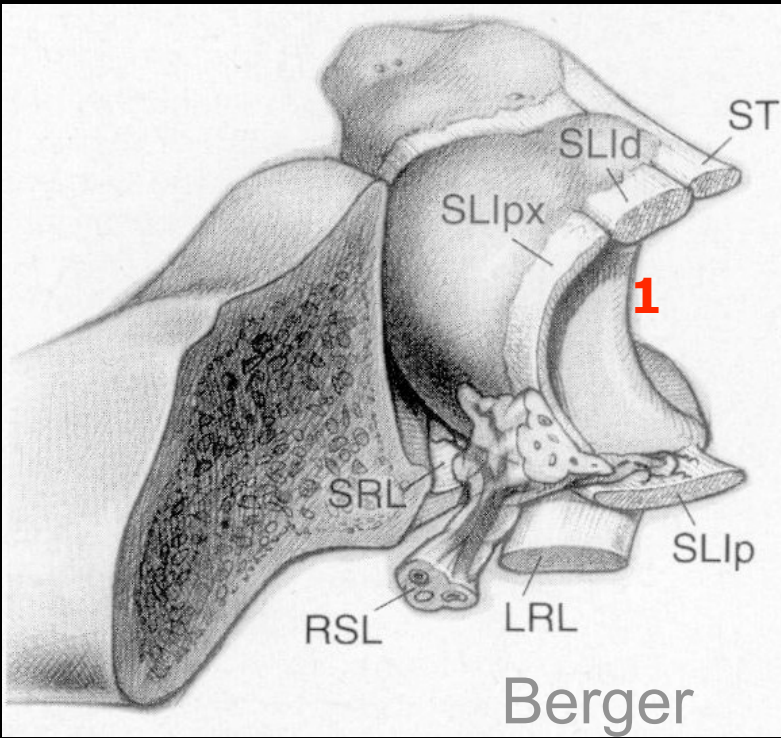


- Scapholunate ligament is classified as intrinsic which means that it has only carpal bone insertions.
- It has a U-shaped structure and joins proximal aspects of scaphoid and lunate bones.
- It consists of thick dorsal (1) and palmar (3) portions and a thinner central portion (2).
- The dorsal aspect is thicker than the palmar one.
- The dorsal and ventral portions are composed of collagen fibers whereas the central portion is composed of fibrocartilage.

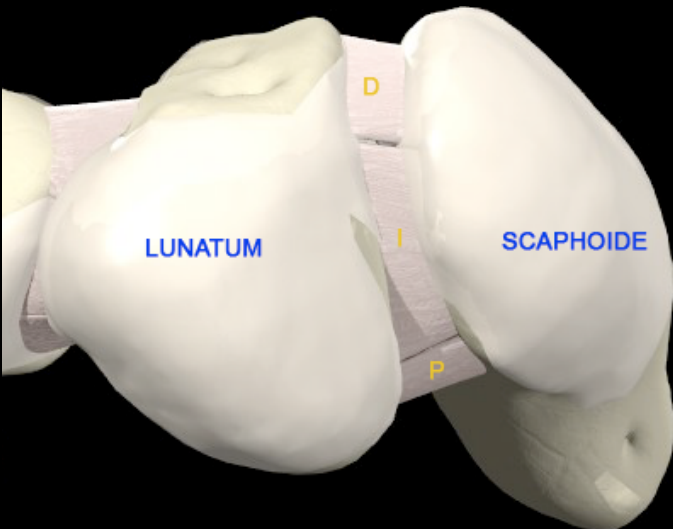


Anatomy, biomechanics and natural history of scapholunate ligamentous injuries. S Berdia, SW Wolfe. Atlas Hand Clin (8) 2003 191-199

ANATOMY

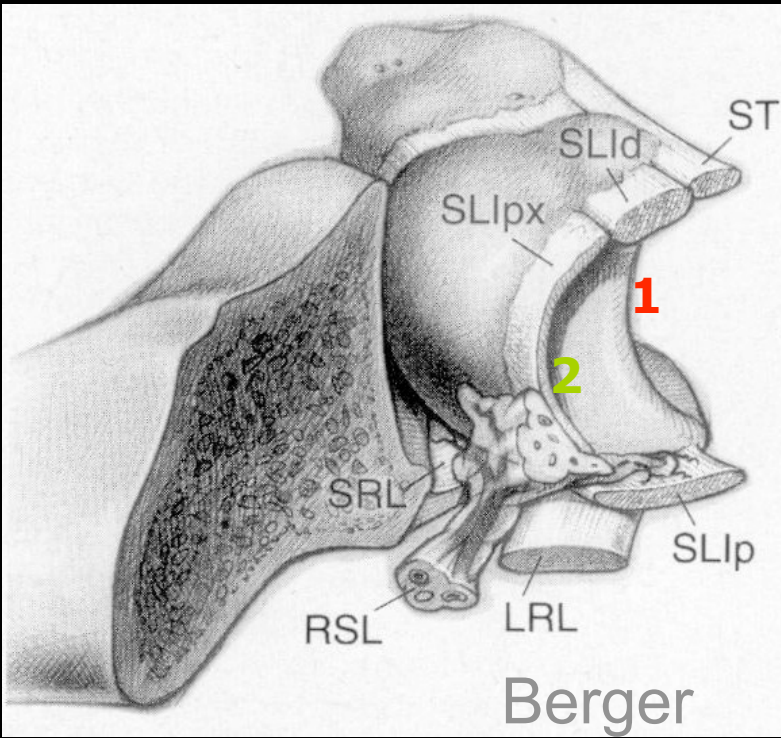


- Scapholunate ligament is classified as intrinsic which means that it has only carpal bone insertions.
- It has a U-shaped structure and joins proximal aspects of scaphoid and lunate bones.
- It consists of thick dorsal (1) and palmar (3) portions and a thinner central portion (2).
- The dorsal aspect is thicker than the palmar one.
- The dorsal and ventral portions are composed of collagen fibers whereas the central portion is composed of fibrocartilage.

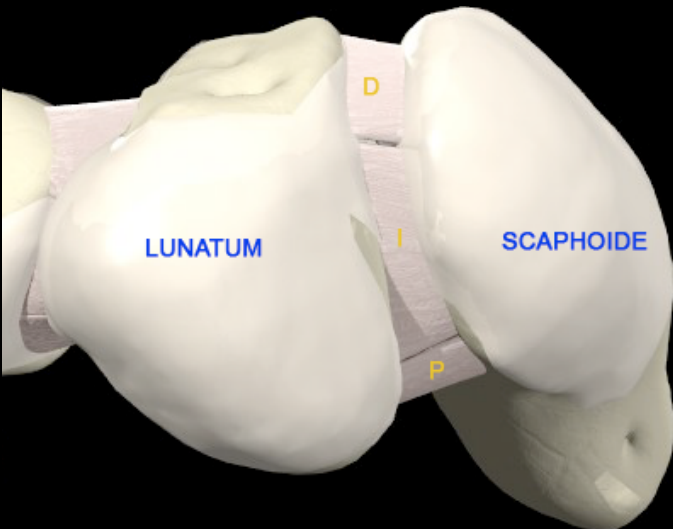


Anatomy, biomechanics and natural history of scapholunate ligamentous injuries. S Berdia, SW Wolfe. Atlas Hand Clin (8) 2003 191-199

ANATOMY

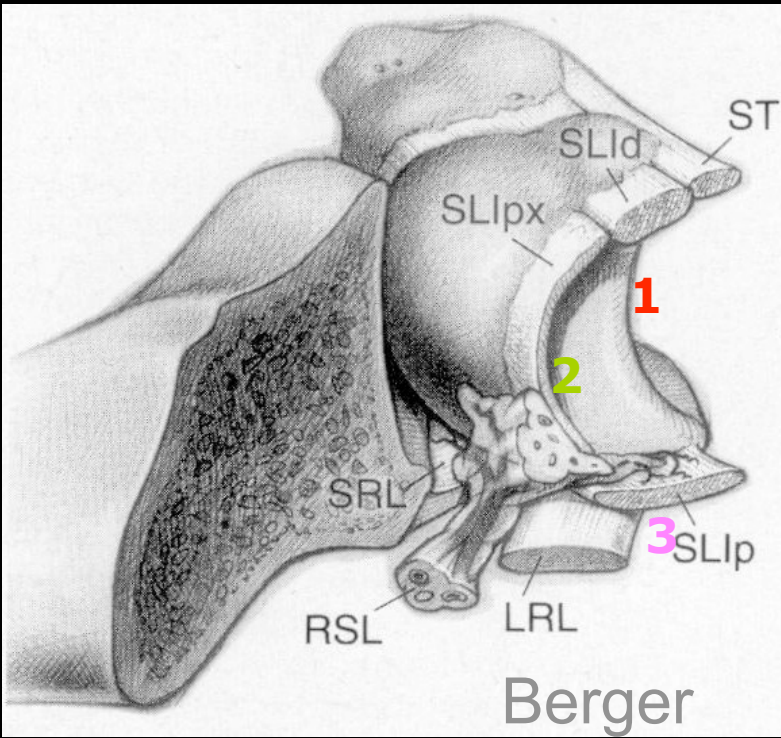


- Scapholunate ligament is classified as intrinsic which means that it has only carpal bone insertions.
- It has a U-shaped structure and joins proximal aspects of scaphoid and lunate bones.
- It consists of thick dorsal (1) and palmar (3) portions and a thinner central portion (2).
- The dorsal aspect is thicker than the palmar one.
- The dorsal and ventral portions are composed of collagen fibers whereas the central portion is composed of fibrocartilage.

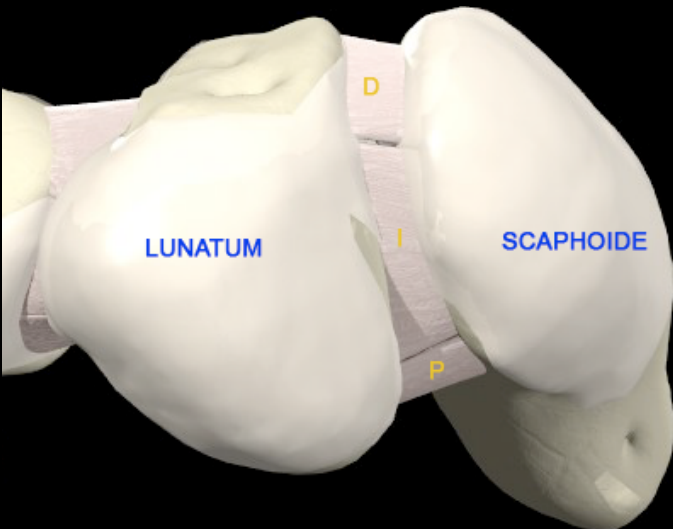


Anatomy, biomechanics and natural history of scapholunate ligamentous injuries. S Berdia, SW Wolfe. Atlas Hand Clin (8) 2003 191-199

ANATOMY



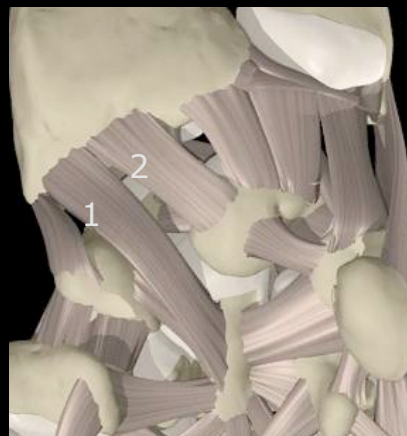- Scapholunate ligament is classified as intrinsic which means that it has only carpal bone insertions.
- It has a U-shaped structure and joins proximal aspects of scaphoid and lunate bones.
- It consists of thick dorsal (1) and palmar (3) portions and a thinner central portion (2).
- The dorsal aspect is thicker than the palmar one.
- The dorsal and ventral portions are composed of collagen fibers whereas the central portion is composed of fibrocartilage.



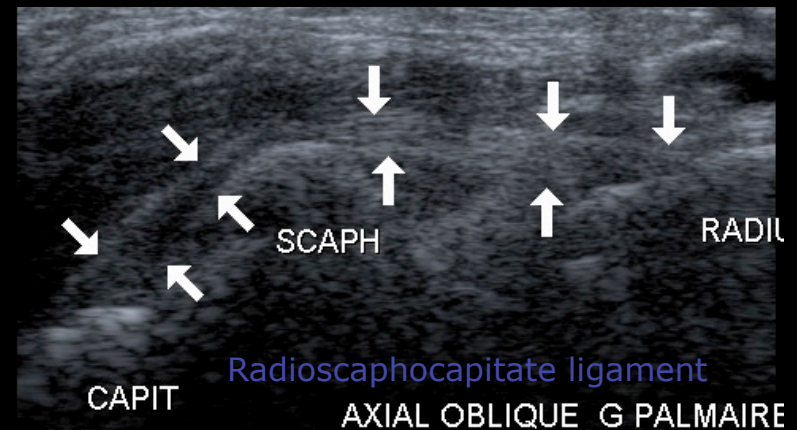
Anatomy, biomechanics and natural history of scapholunate ligamentous injuries. S Berdia, SW Wolfe. Atlas Hand Clin (8) 2003 191-199

PATHOLOGY

- Ligament injury follows wrist trauma in hyperextension and ulnar deviation. Transverse compression and carpal supination then occur and are responsible for ligament injury.
- Different kinds of lesions can be noted and involve one to three components of the ligament : distension, partial or complete tear.
- The main risk of a ligamentous lesion is a quick and progressive wrist instability.
- Recent works* have shown that a scapholunate dissociation is not only due to a scapholunate injury but also to extrinsic ligaments (mainly radioscaphocapitate, palmar radiolunate and palmar scaphotriquetral).



1. Radioscaphocapitate ligament
2. Radiolunate ligament



* Nicolas H. Theumann, Ghazal Etehami, Bertrand Duvoisin, Max Wintermark, Pierre Schnyder, Nicolas Favarger, and Louis A. Gilula
Association between Extrinsic and Intrinsic Carpal Ligament Injuries at MR Arthrography and Carpal Instability at Radiography: Initial Observations
Radiology 2006 238: 950-95

PATHOLOGY

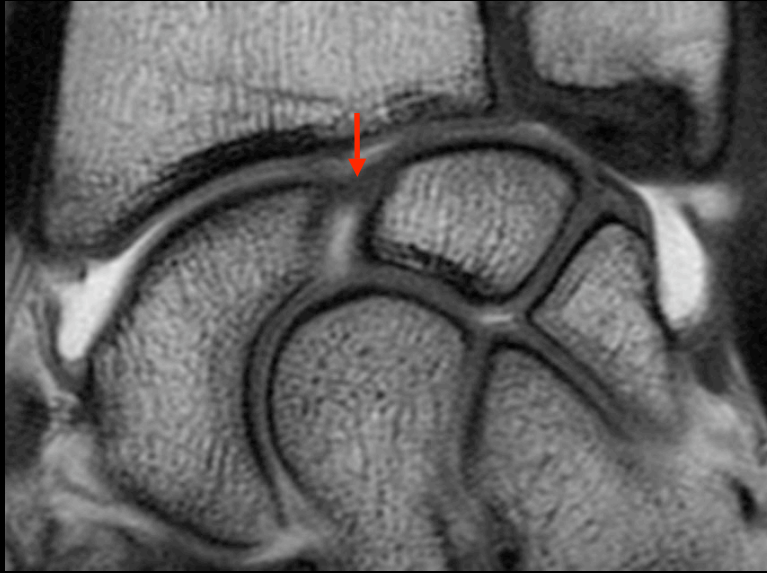
Clinical issues:

- **Most common symptoms:** pain and soft tissue swelling involving dorsoradial wrist
- **Clinical profile:**
 - pain and tenderness anatomic snuffbox
 - Watson test (scaphoid shift test): pain on ulnar to radial deviation
 - audible click at scapholunate interval

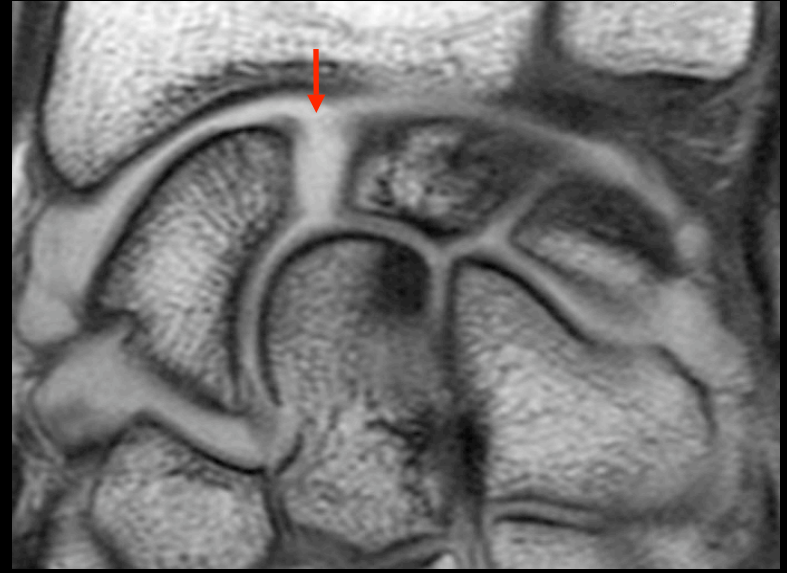Classification:

- **Acute (< 6 weeks):**
 - stable: partial ligament disruption
 - unstable (dynamic or static): complete ligament disruption
- **Chronic:**
 - stable, unstable or fixed
 - dissociative grade with DISI deformity
 - Scapholunate advanced collapse (SLAC): progressive pancarpal arthrosis

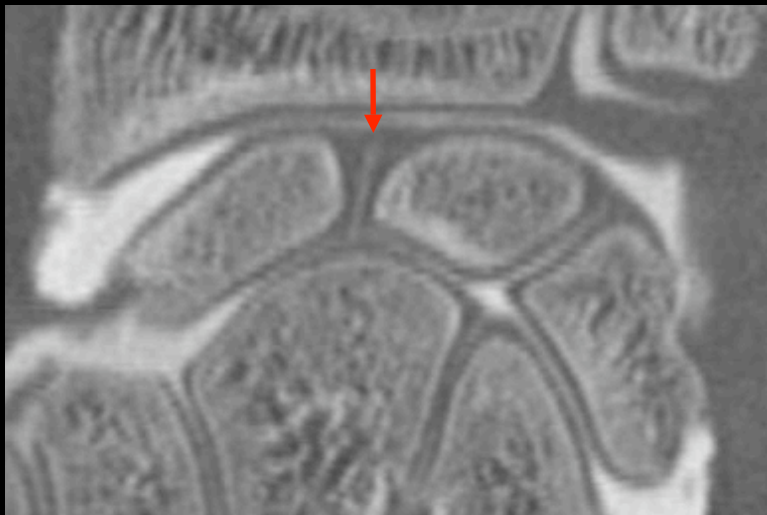Scapholunate ligament tear cannot be seen on plain radiographs. Arthro-CT, Arthro-MRI or arthroscopy allow to see the lesion directly.



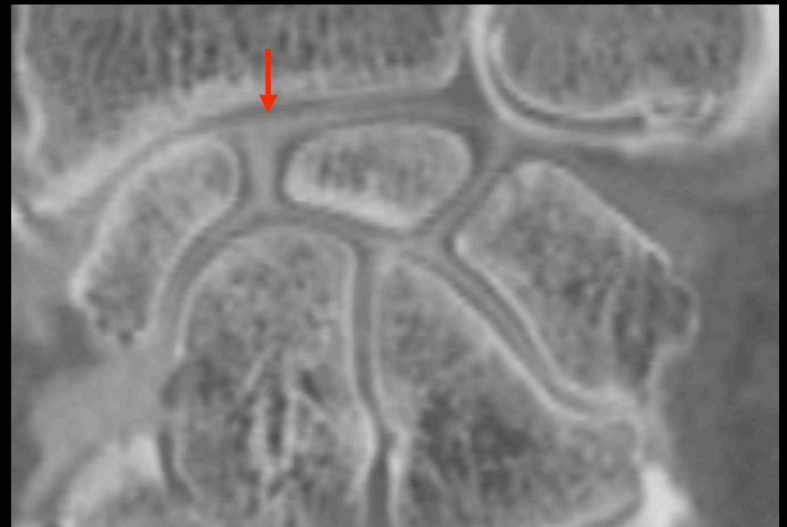Normal aspect: Arthro-MR



SL ligament tear: Arthro-MR

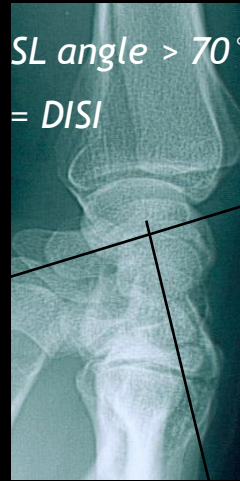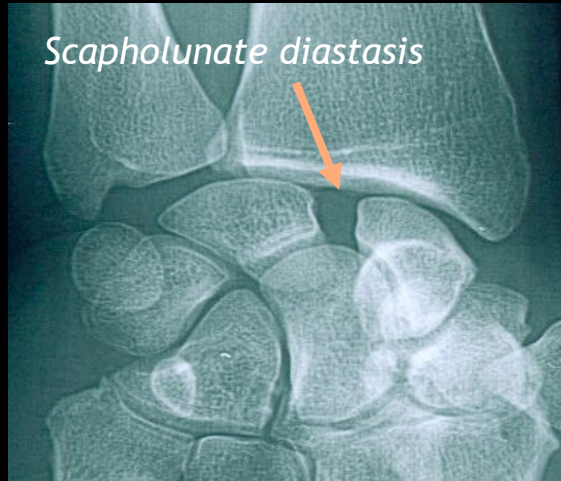


Normal aspect: Arthro-CT

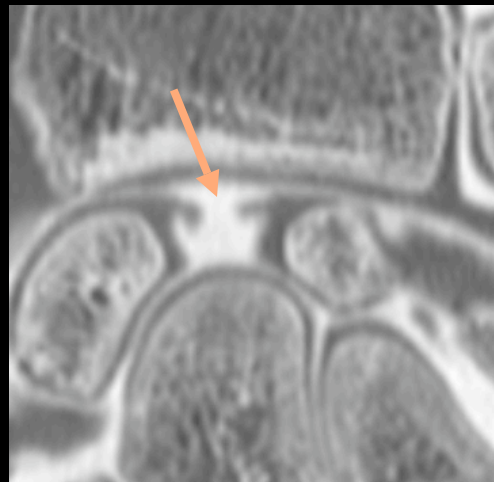

SL ligament tear: Arthro-CT

When a lesion remains unknown, palmar flexion of scaphoid bone and dorsal extension of lunate occur which leads to DISI (Dorsal Intercalated Segmented Instability) and interosseous diastasis (dissociative grade). Diagnosis of instability is then made by plain radiographs or dynamic radiographic studies.



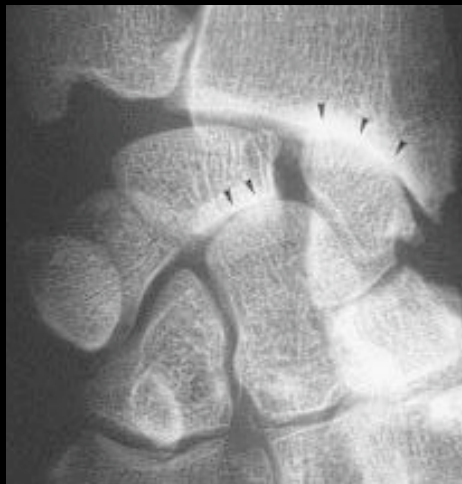Plain radiographs, Arthro-CT or Arthro-MRI show widening of scapholunate gap. Pathologic widening is superior to 3mm.



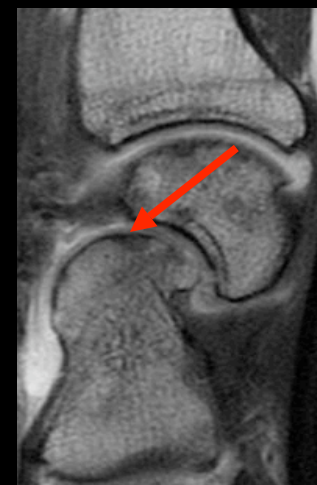Arthro-CT shows scapholunate ligament disruption and pathologic widening of the scapholunate gap.

There is a gradual stereotyped evolution in wrist osteoarthritis called SLAC (Scapho-Lunate Advanced Collapsed): progressive proximal capitate migration, radioscaphoid and capitulunate arthrosis.

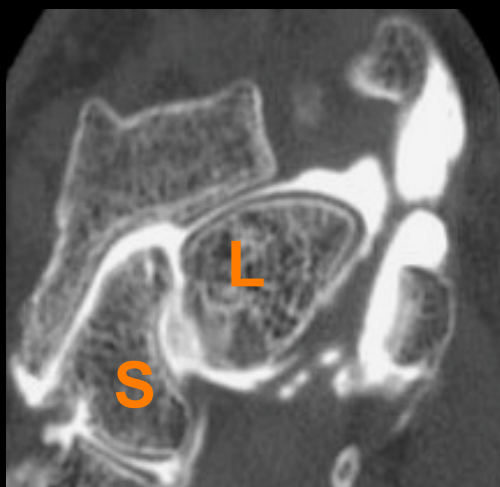Diagnosis can be made by plain radiographs, arthro-CT or arthro-MRI.



X-Rays show a widening of scapholunate gap and narrowing of radioscaphoid and capitulunate spaces (SLAC grade 3).

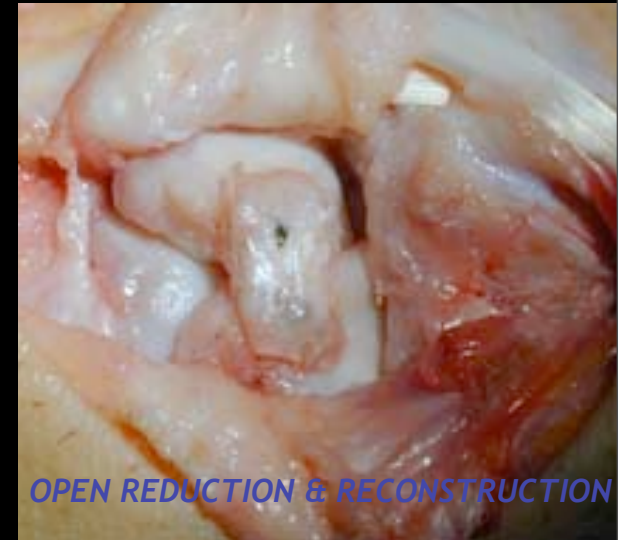
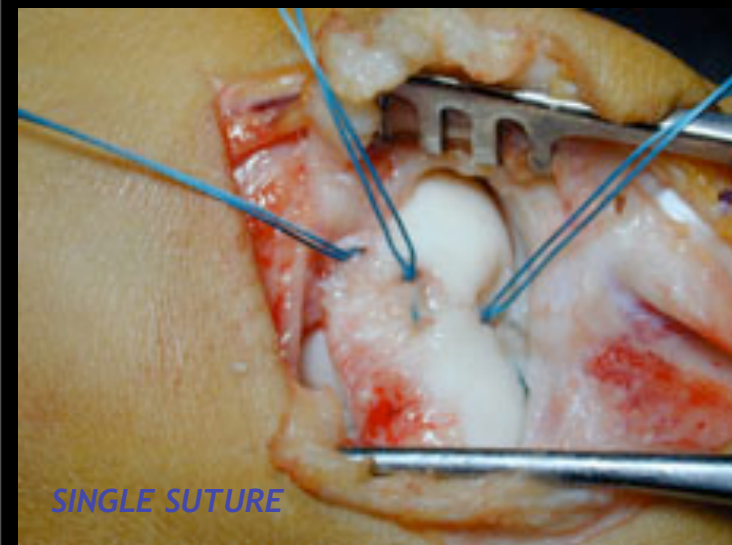


Arthro-MRI shows dorsal bascule of lunate bone and subchondral bone lesions of lunate and capitate bones (SLAC grade 3).

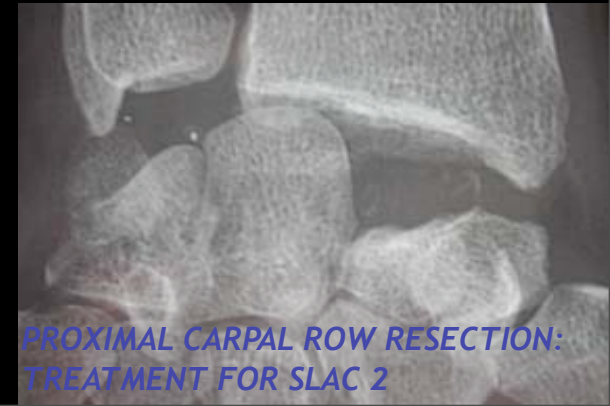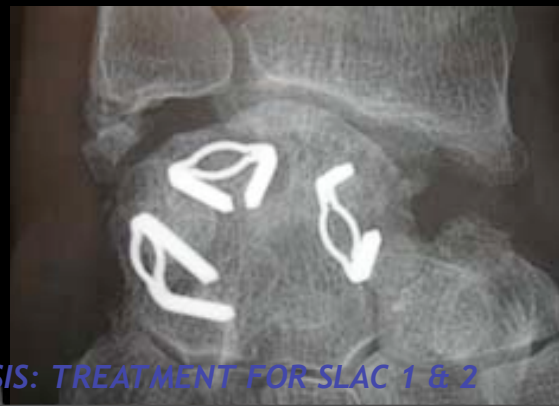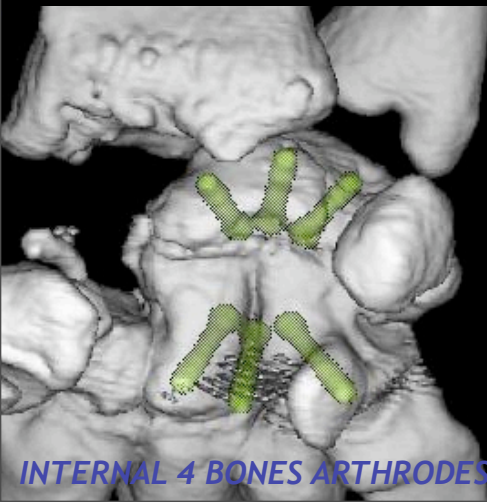


Arthro-CT shows radioscaphoid narrowing space and chondral lesions.

Therapeutic options vary considerably depending on the time elapsed since the injury, the degree of stability and the age and personal living circumstances of the patient. Conservative treatment is for partial and stable lesions. Surgical repair has good results when done less than six weeks after injury.

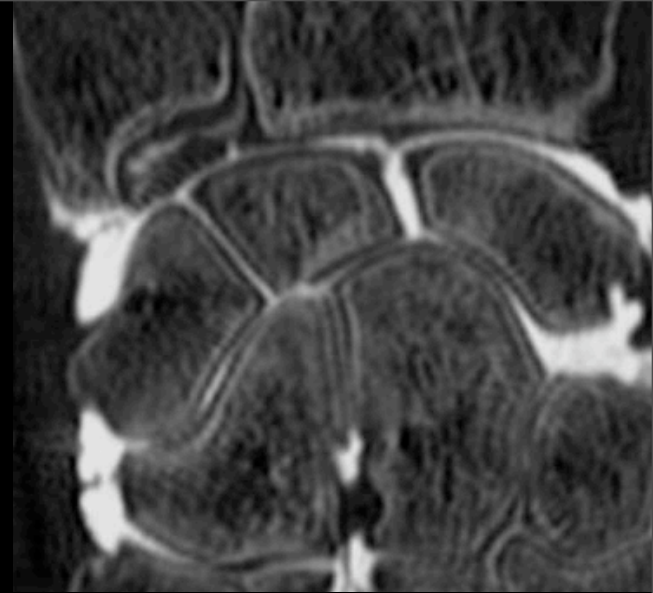
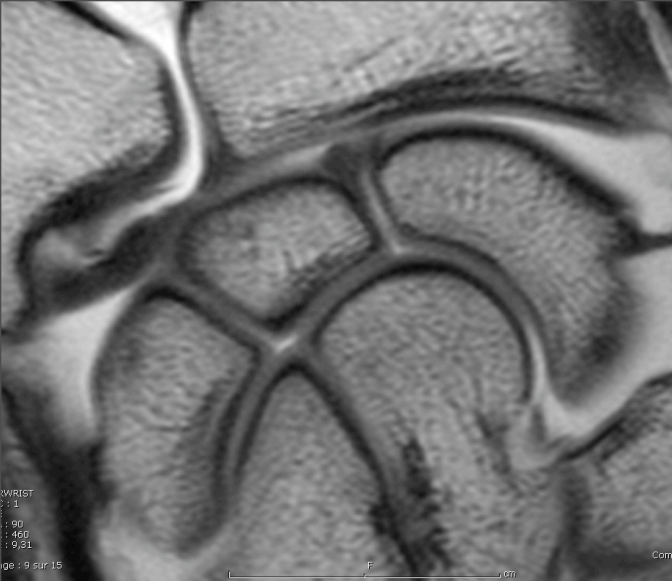


Chronic lesions with osteoarthritis require palliative surgical treatment.

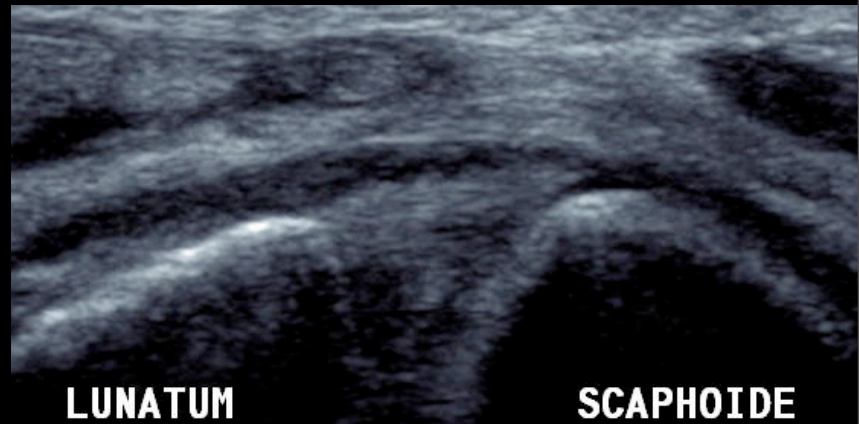
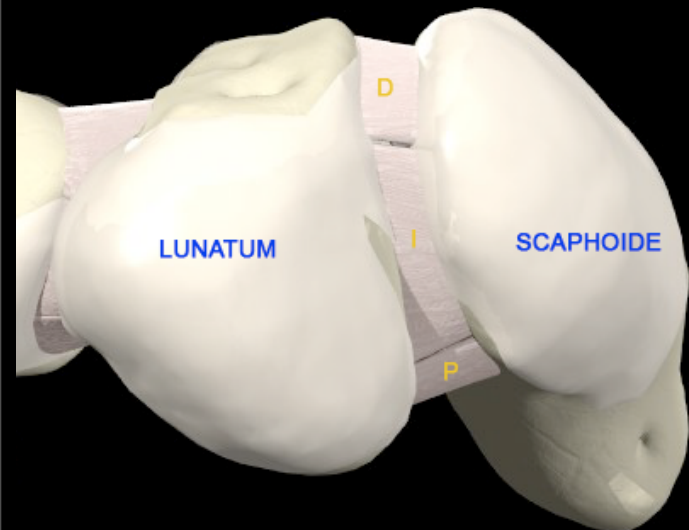


INTERNAL 4 BONES ARTHRODESIS: TREATMENT FOR SLAC 1 & 2

PROXIMAL CARPAL ROW RESECTION: TREATMENT FOR SLAC 2



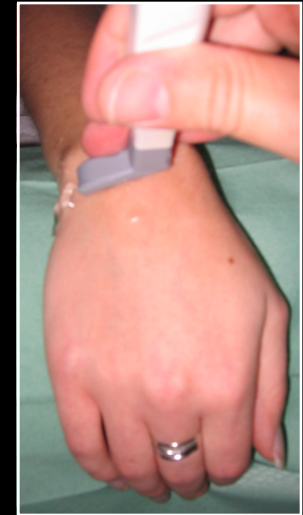PICTORIAL REVIEW



3-A. NORMAL US SCAPHOLUNATE ASPECTS

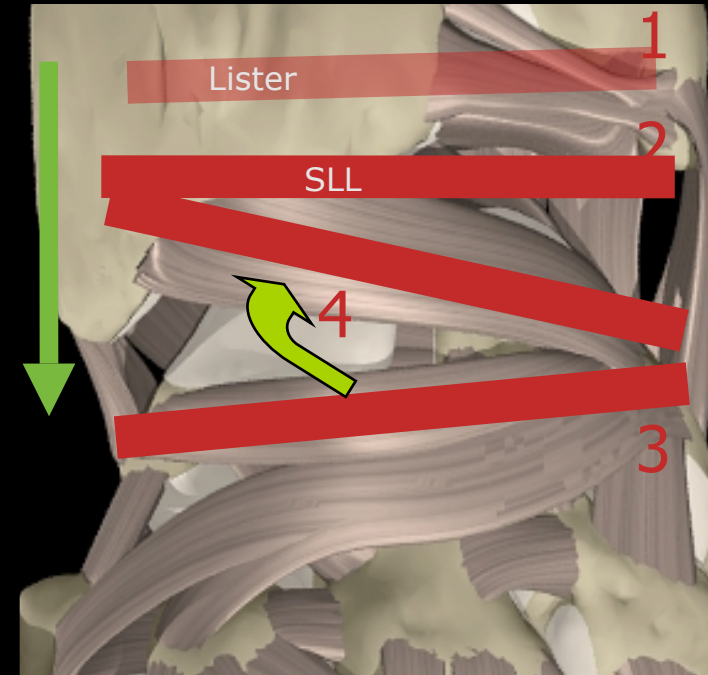
Principles

- Superficial probe
- High-frequency transducer
- Bilateral study (to avoid degenerative perforations)
- Transverses imaging planes
- Dynamic examination in ulnar deviation and closed



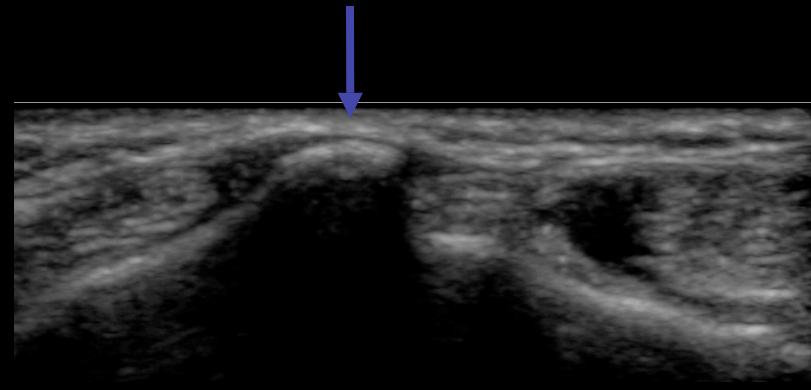
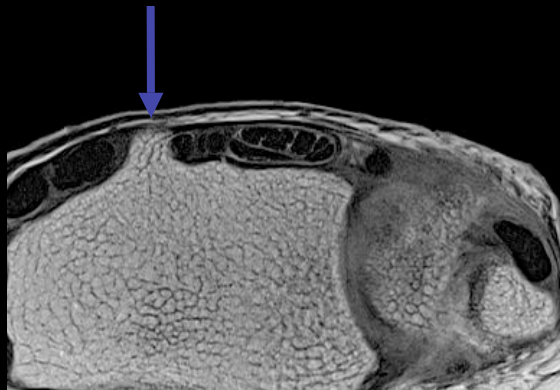
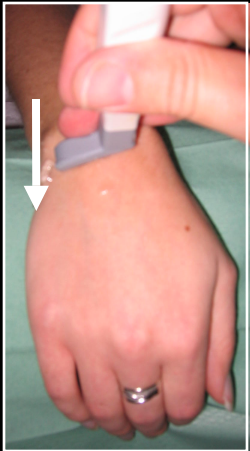
Method

- The dorsal portion is the most important structure to analyse
- Standardized method (dorsal ligaments):
 - 1: Lister's tubercle
 - 2: Dorsal scapholunate ligament
 - 3: Dorsal intercarpal ligament
 - 4: Dorsal radiocarpal ligament (involving an oblique direction)



Dorsal band

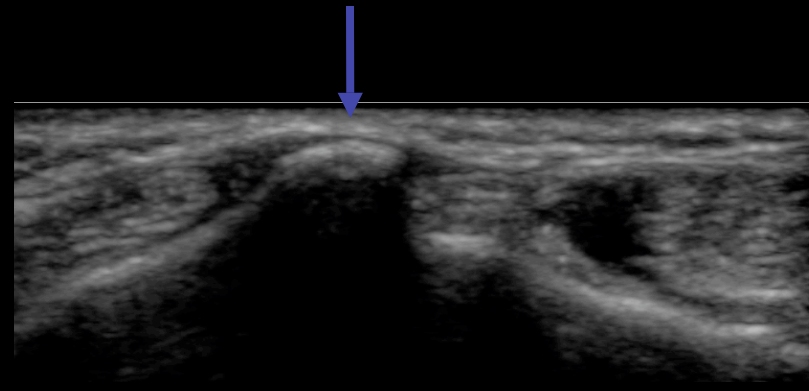
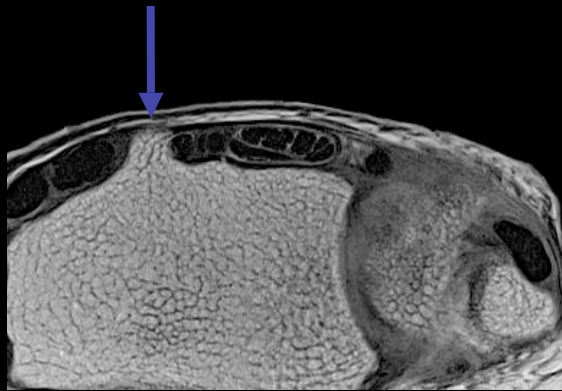
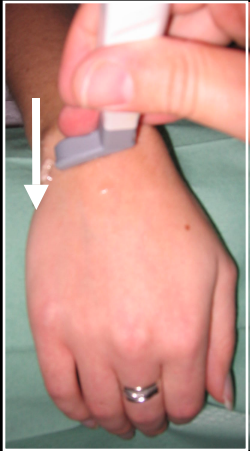
- The dorsal scapholunate ligament is located distally and medially to Lister's tubercle.
- 1st step: Lister's tubercle repair



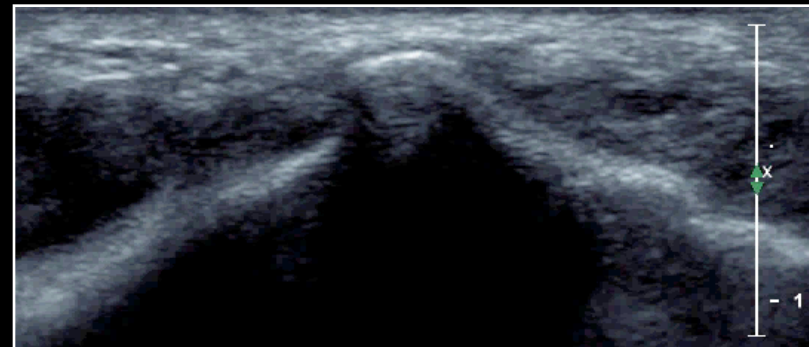
- 2nd step: distally move the probe
- 3rd step: **hyperechoic fibrillar structure** repair bridging the hyperechoic cortex of both bones corresponding to scapholunate ligament

Dorsal band

- The dorsal scapholunate ligament is located distally and medially to Lister's tubercle.
- 1st step: Lister's tubercle repair

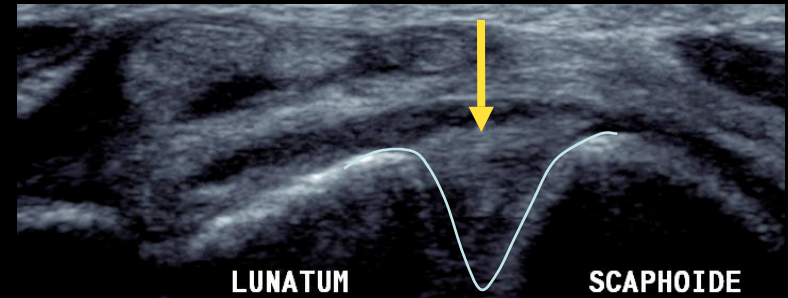


- 2nd step: distally move the probe
- 3rd step: **hyperechoic fibrillar structure** repair bridging the hyperechoic cortex of both bones corresponding to scapholunate ligament



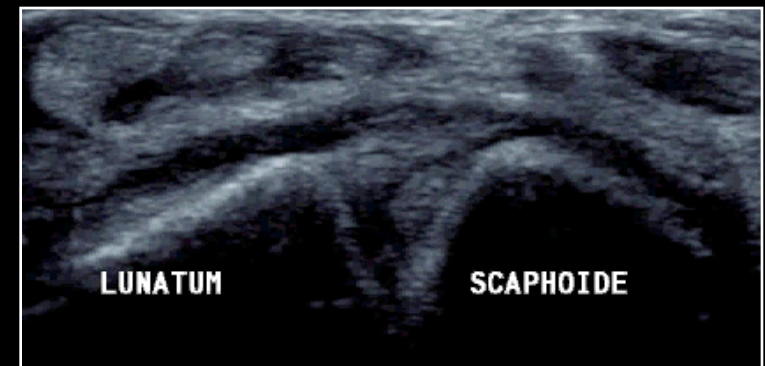
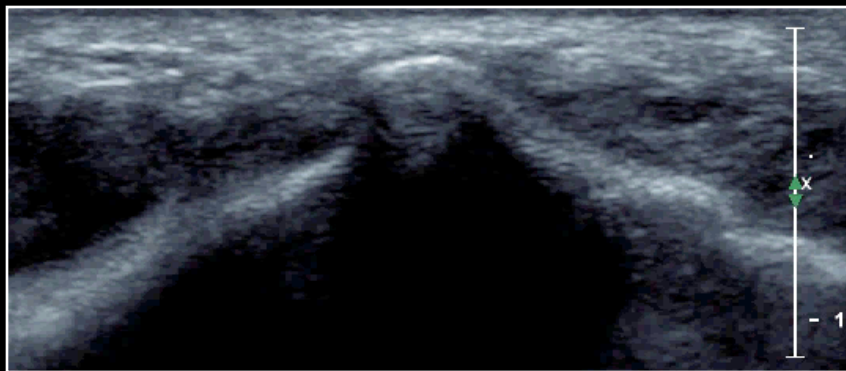
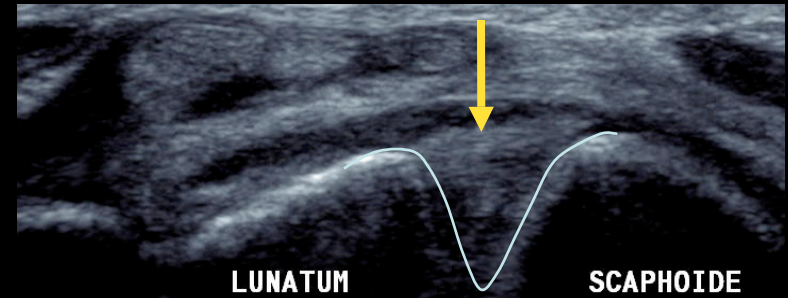
Dorsal band

- **Hyperechoic fibrillar structure** between scaphoid and lunate bones
- Note the V-shaped aspect of scapholunate space
- Mean thickness: 1,1 mm
- Mean interosseous distance: 4,2 mm (Jacobson)
- Almost constant visibility: 97% (Boutry)
- Visibility increased by tissue harmonic imaging (Kendi)



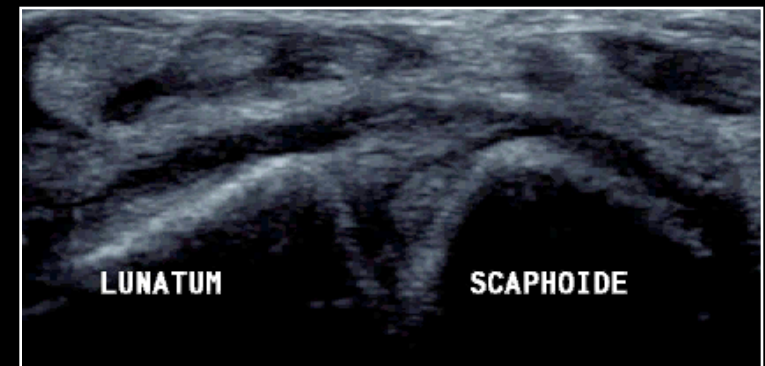
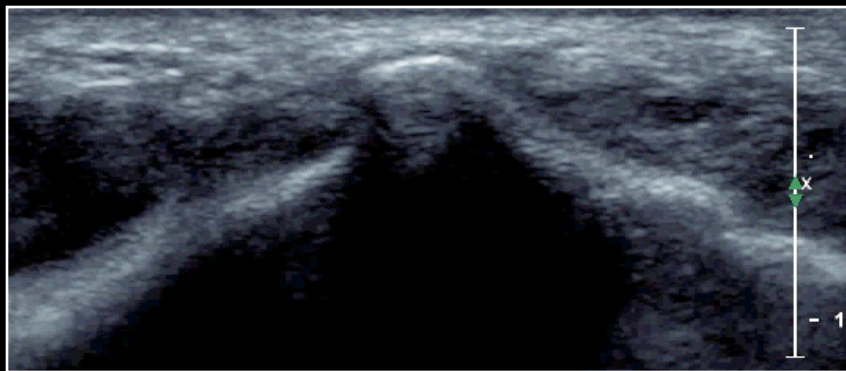
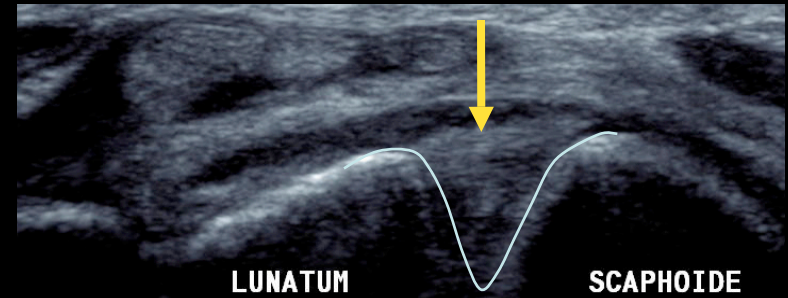
Dorsal band

- **Hyperechoic fibrillar structure** between scaphoid and lunate bones
- Note the V-shaped aspect of scapholunate space
- Mean thickness: 1,1 mm
- Mean interosseous distance: 4,2 mm (Jacobson)
- Almost constant visibility: 97% (Boutry)
- Visibility increased by tissue harmonic imaging (Kendi)



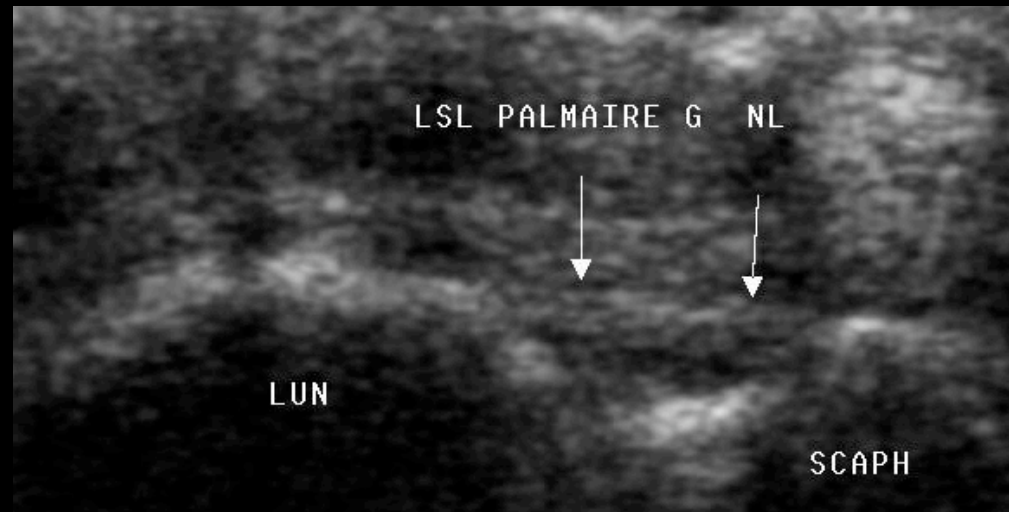
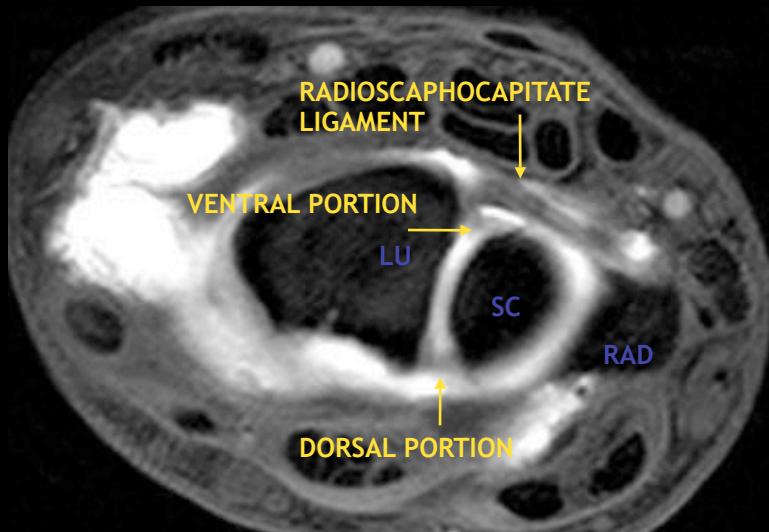
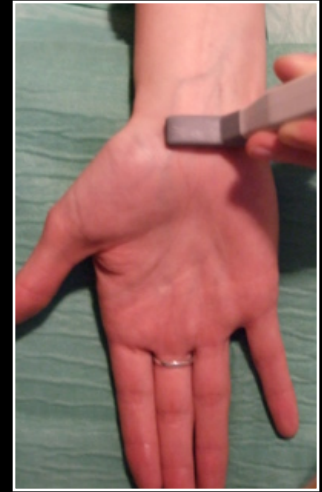Dorsal band

- **Hyperechoic fibrillar structure** between scaphoid and lunate bones
- Note the V-shaped aspect of scapholunate space
- Mean thickness: 1,1 mm
- Mean interosseous distance: 4,2 mm (Jacobson)
- Almost constant visibility: 97% (Boutry)
- Visibility increased by tissue harmonic imaging (Kendi)



Ventral band

- 1st step: repair the floor of carpal tunnel which is made of palmar scaphotriquetral ligament
- 2nd step: repair hyperechoic fibrillar structure bridging the hyperechoic cortex of both bones
- Thinner band
- Under the radioscaphocapitate and palmar scaphotriquetral ligaments
- Completely visible: 81% (Boutry)



3-B.US patterns of Scapholunate ligament tears

Ultrasonography must check the ligament integrity.

Lack of visibility is not synonymous of rupture because of the frequency of degenerative changes. Examination must be performed in both wrists in case of pathologic changes.

Two studies have shown the role of ultrasound in diagnosis of ligament tears:

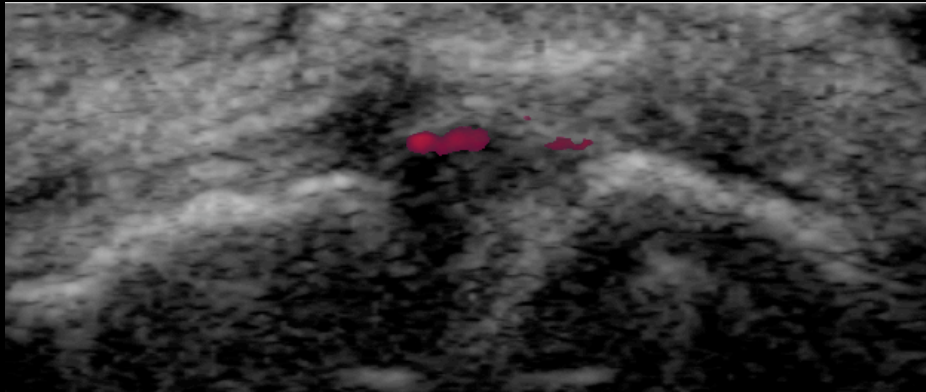
- Finlay: sensitivity; 100%, specificity: 100%, accuracy: 100%
- Dao: sensitivity: 46,2%, specificity: 100%, accuracy: 89,1%

Several pathologic aspects may occur:

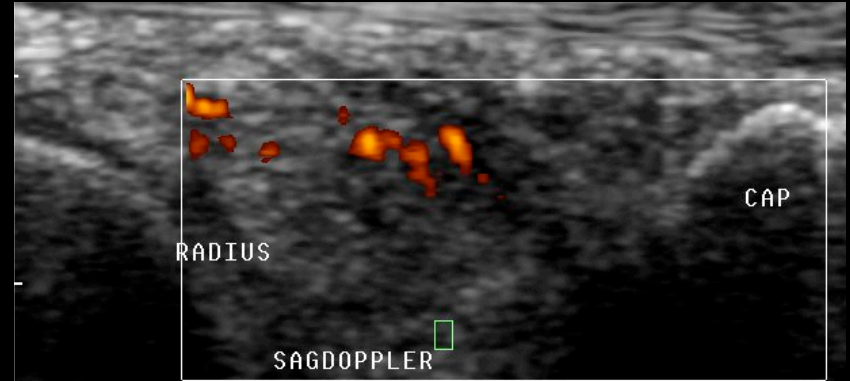
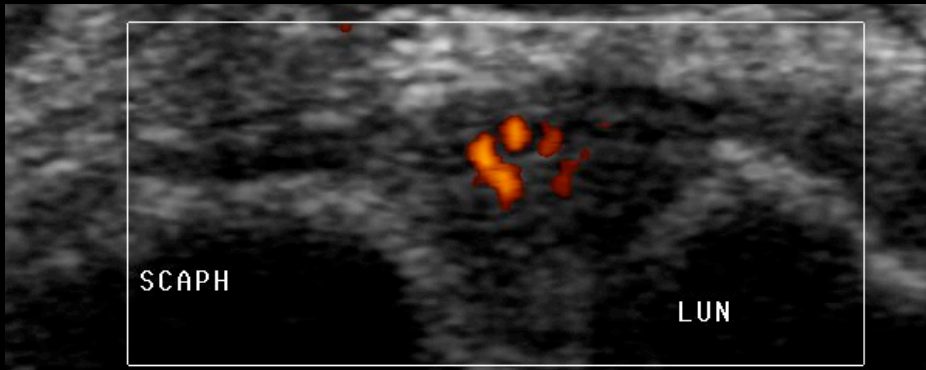
- Distension
- Partial or complete disruption (one to three ligamentous portions)
- Spontaneous or dynamic scapholunate diastasis

DISTENSION OF SCAPHOLUNATE LIGAMENT

- First grade of ligament injury
- Not responsible alone for instability

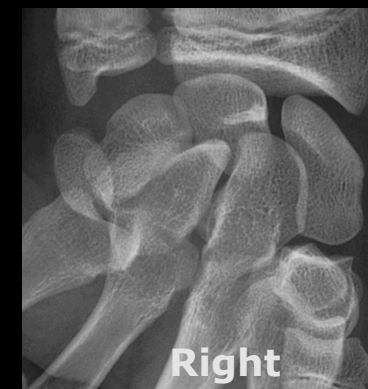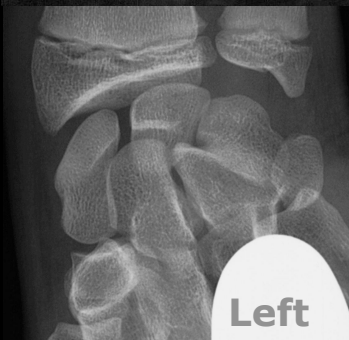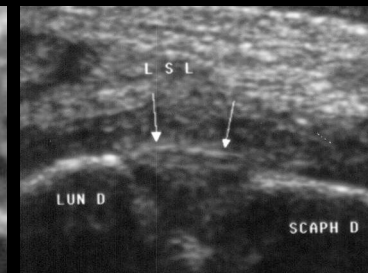
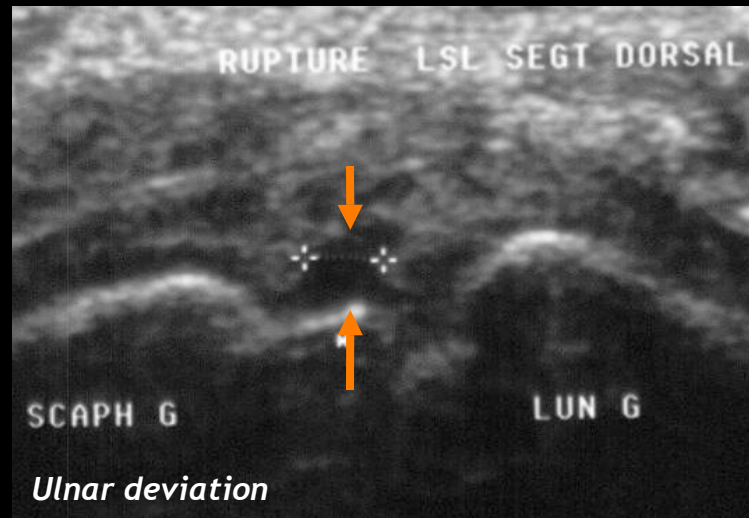
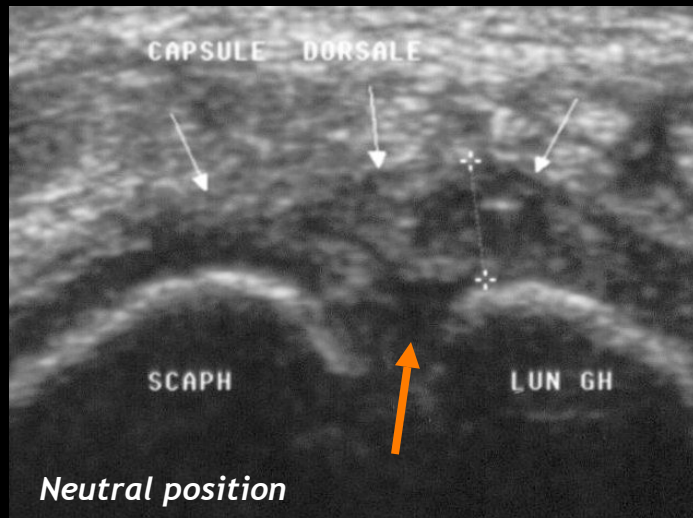


- Loss of fibrillar aspect
- Thick hypoechoic ligament
- No anechoic scapholunate gap
- No diastasis
- Hyperhemia at colour doppler



PARTIAL TEARS

- Only one portion of the ligament gets injured

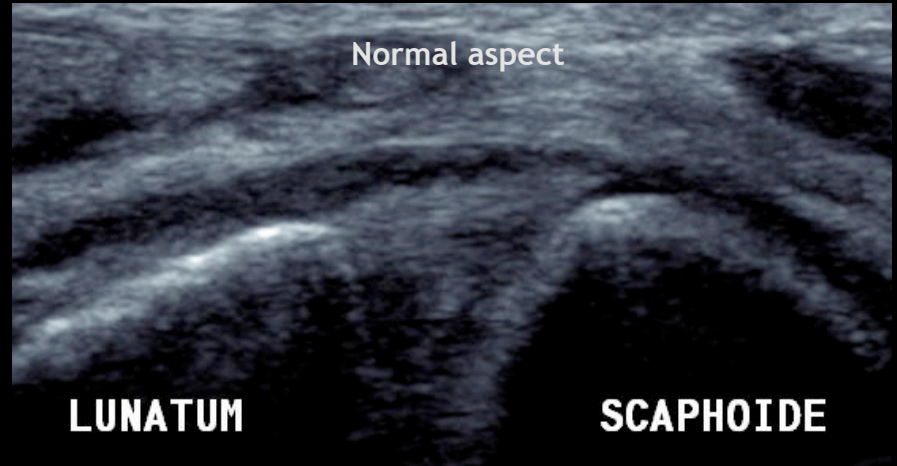
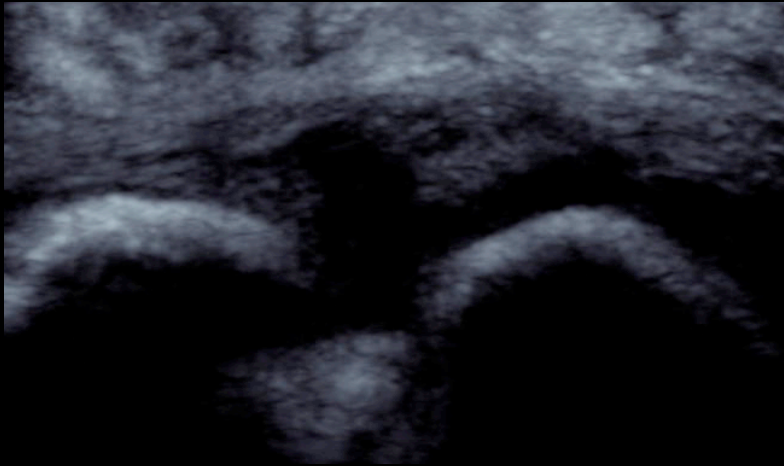


- *Transverse sonogram of dorsal portion of scapholunate ligament shows anechoic central rupture increased by ulnar deviation.*
- *No clinic or radiographic instability.*
- *Normal ventral portion.*

- It can also mean that the tear doesn't cross through the whole ligamentous thickness

COMPLETE TEARS

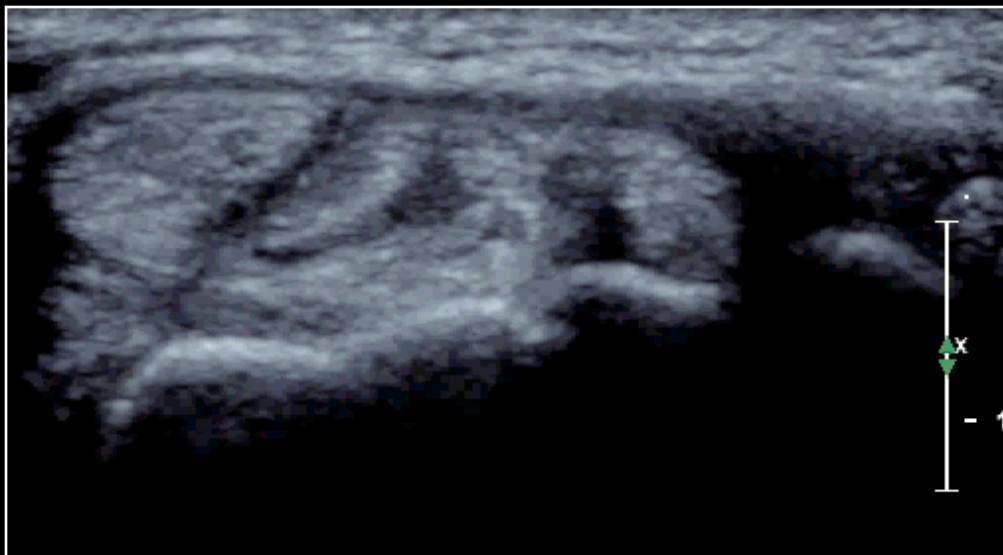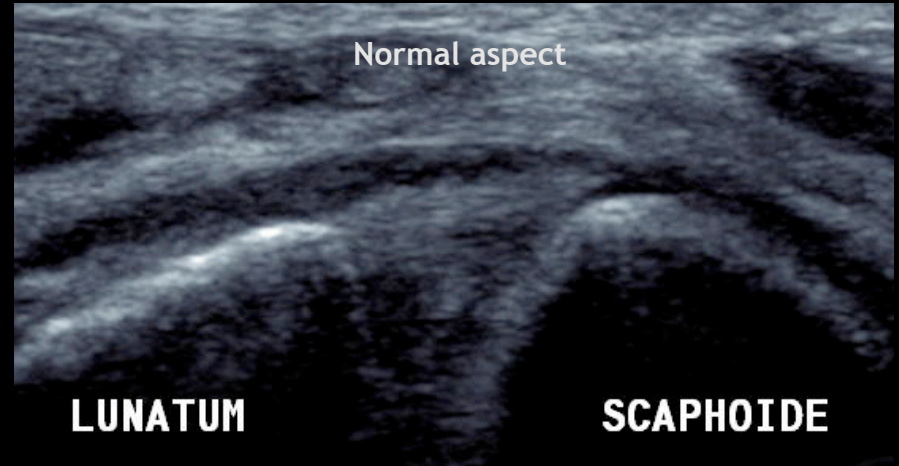
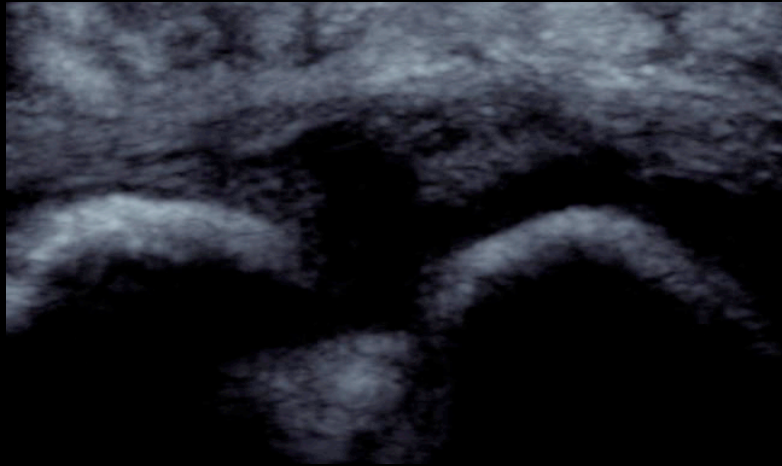
- No ligament visibility
- Anechoic scapholunate gap



Care should be taken not to mistake the dorsal radiotriquetral ligament for the scapholunate ligament. The dorsal radiotriquetral ligament has the same fibrillar hyperechoic appearance but has an oblique direction and passes superficially onto lunate and scaphoid bones and scapholunate ligaments.

COMPLETE TEARS

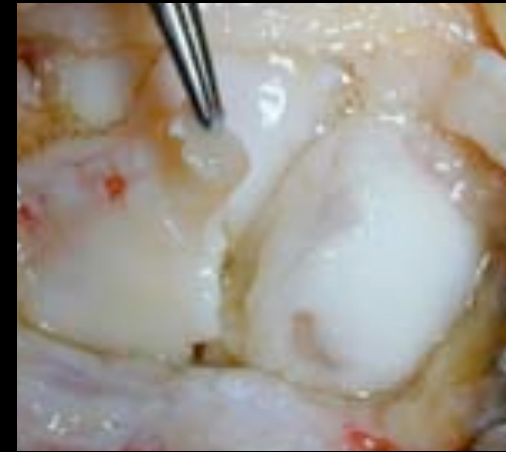
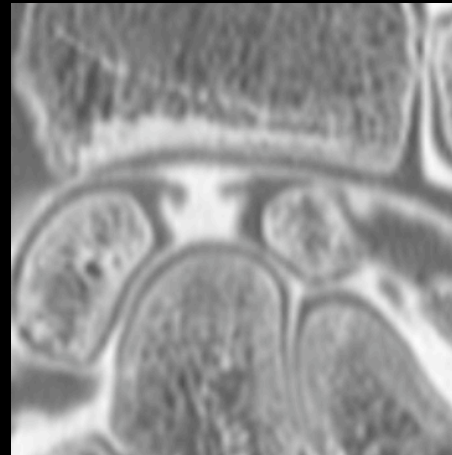
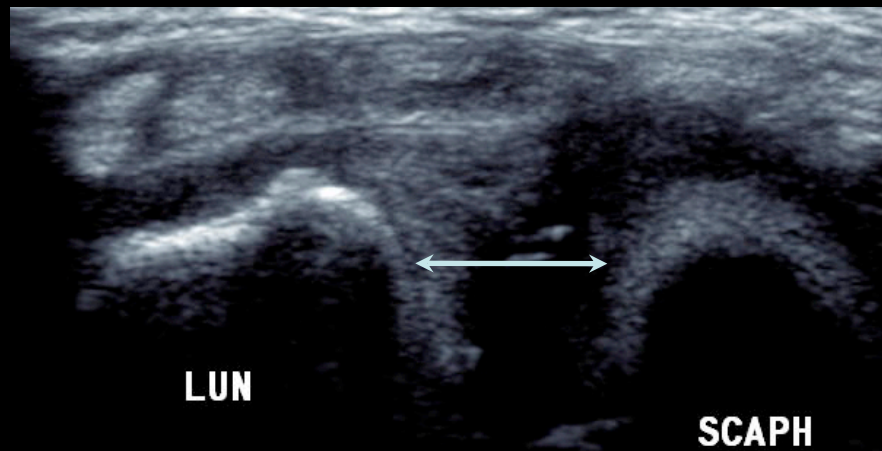
- No ligament visibility
- Anechoic scapholunate gap



Care should be taken not to mistake the dorsal radiotriquetral ligament for the scapholunate ligament. The dorsal radiotriquetral ligament has the same fibrillar hyperechoic appearance but has an oblique direction and passes superficially onto lunate and scaphoid bones and scapholunate ligaments.

COMPLETE TEARS

- Widening of scapholunate distance
- Hypoechogenicity of the scapholunate gap
- No visualization of the ligament at its expected location

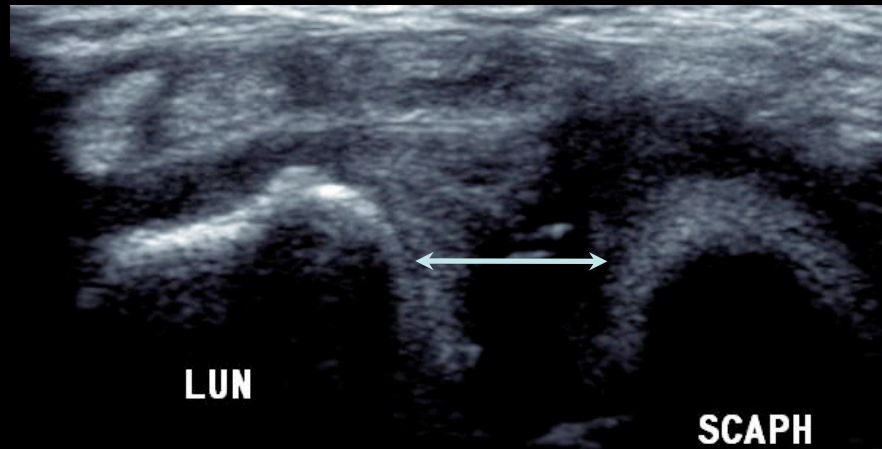


Arthro-CT and arthroscopy confirm ligament tear as described on ultrasonography.

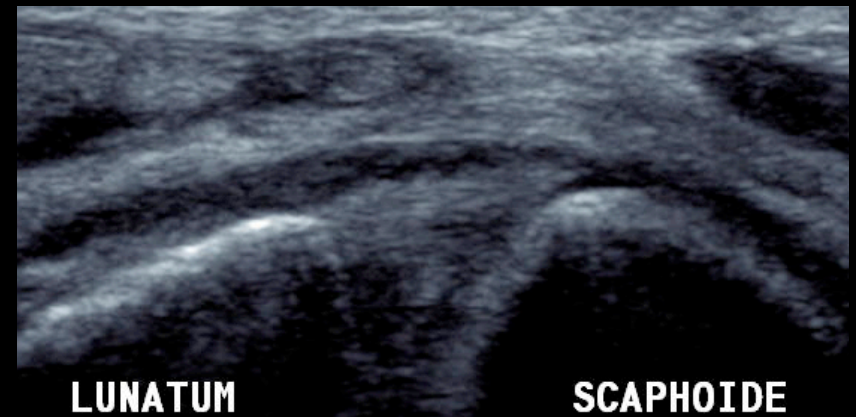- Note that there is no ultrasound reproducible landmark for pathologic scapholunate joint margin width.

COMPLETE TEARS

- Widening of scapholunate distance



- Dynamic examination (closed fist) can be useful to improve scapholunate instability.

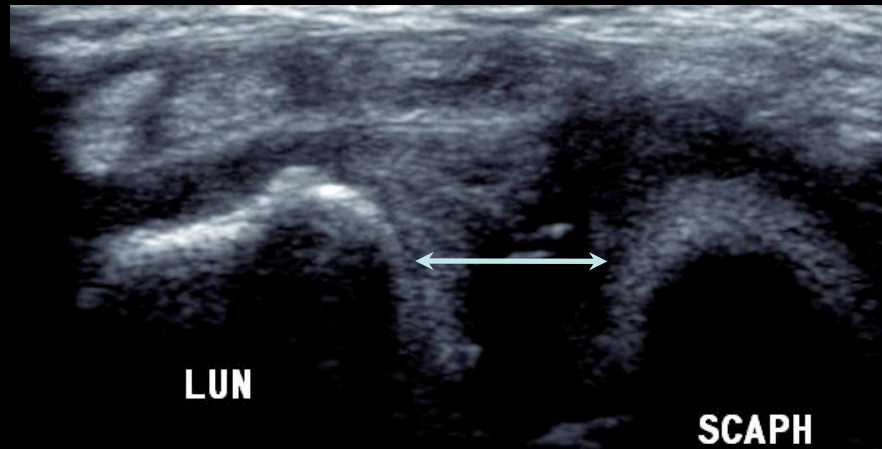


Widening of SL gap only when fist is closed.

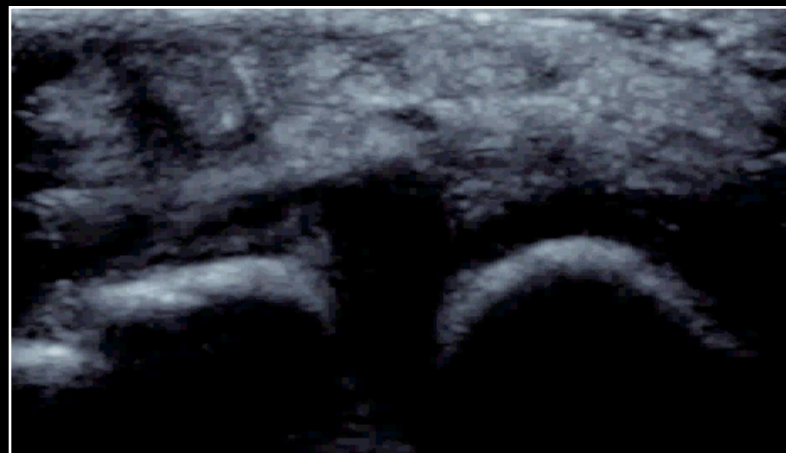Normal aspect

COMPLETE TEARS

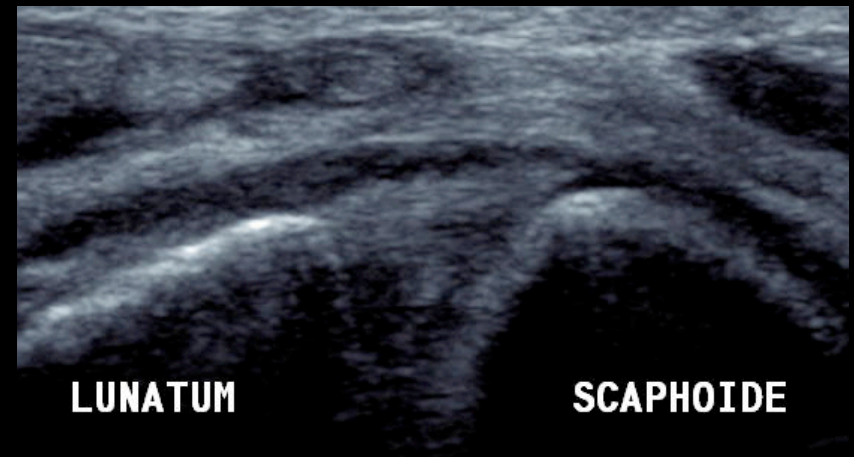
- Widening of scapholunate distance



- Dynamic examination (closed fist) can be useful to improve scapholunate instability.



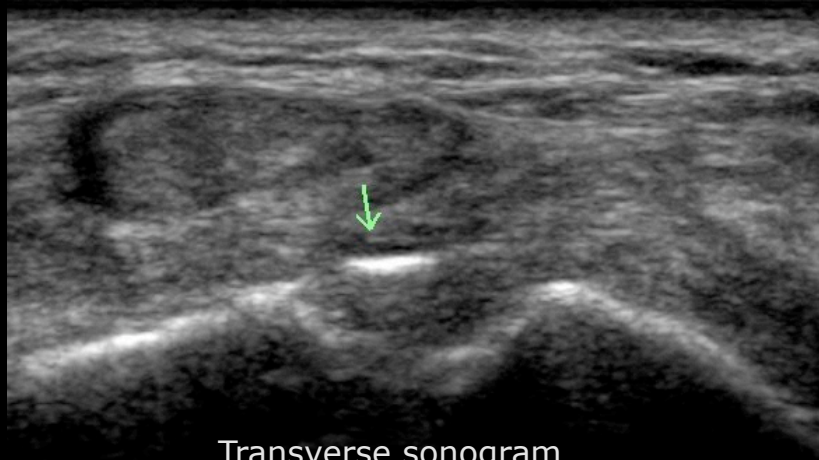Widening of SL gap only when fist is closed.



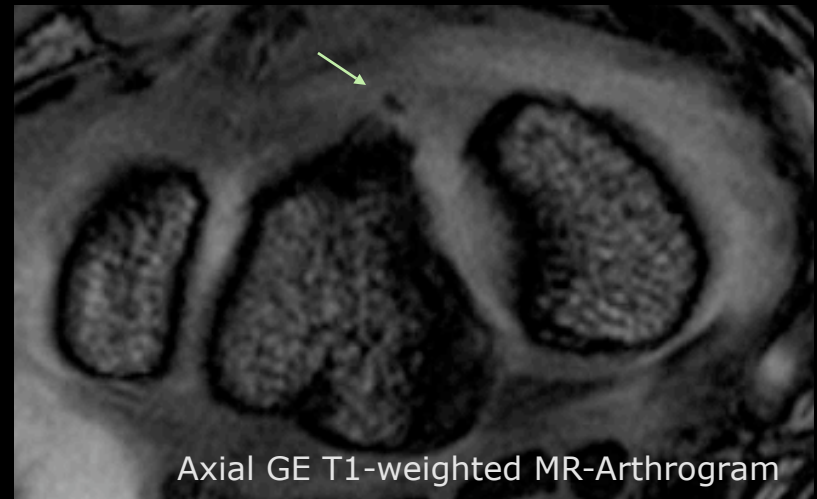
Normal aspect

COMPLETE TEARS

- Cortical avulsion: equivalent to a scapholunate ligament tear
- Infrequent lesion



Transverse sonogram



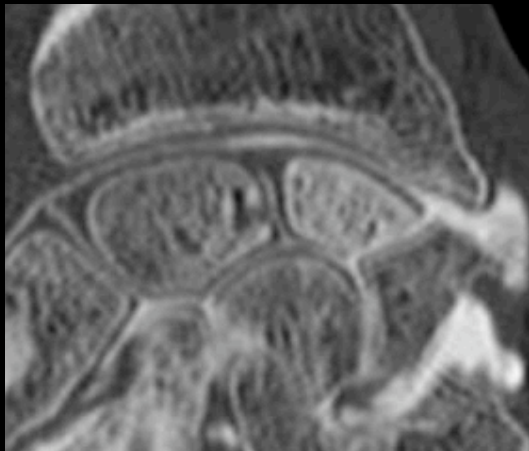
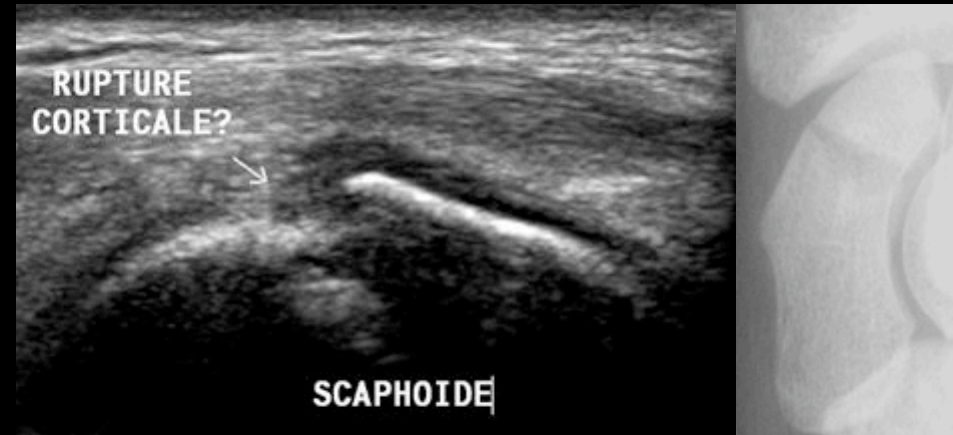Axial GE T1-weighted MR-Arthrogram

- *US shows hyperechoic linear image between scaphoid and lunate bones and thick scapholunate ligament.*
- *Arthro-MR shows cortical avulsion located at the ulnar side of the scapholunate ligament (which is thick and has lost its normal hyposignal).*
- Note that calcified changes of scapholunate ligament can be seen in degenerative changes.

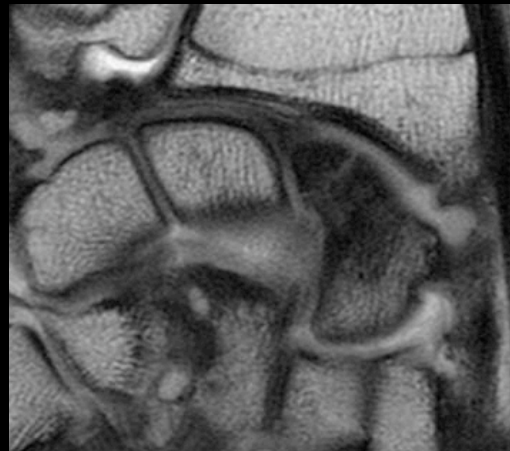
3-c. Differential diagnosis

SCAPHOID FRACTURES

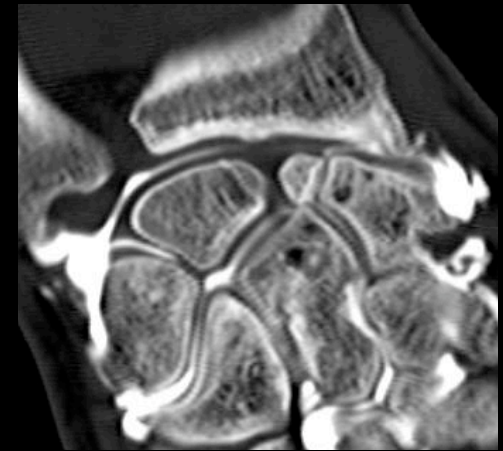- Most common site of occult fractures
- Step-off deformity/Cortical disruption
= diagnostic key
- Focal hematoma or hemarthrosis: indirect signs
- Early diagnosis and treatment decrease the rate of complications



Arthro-CT shows proximal pole sclerosis (avascular necrosis) and transverse fracture line.



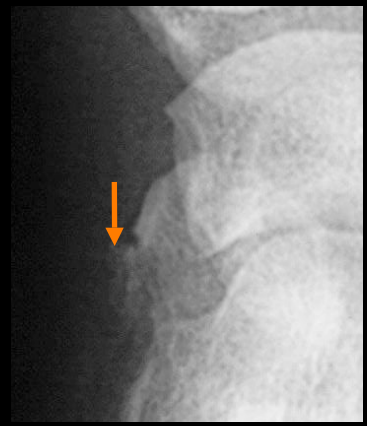
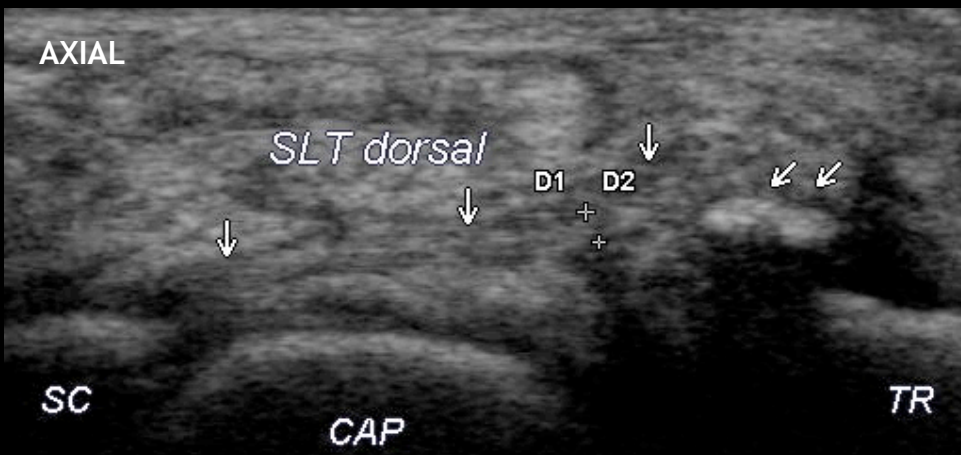
Arthro-MR shows hypointense marrow edema both proximal and distal to the scaphoid fracture site (avascular necrosis).



Arthro-CT shows scaphoid non-union advanced collapse (SNAC) with chondral loss between distal pole scaphoid and distal radius.

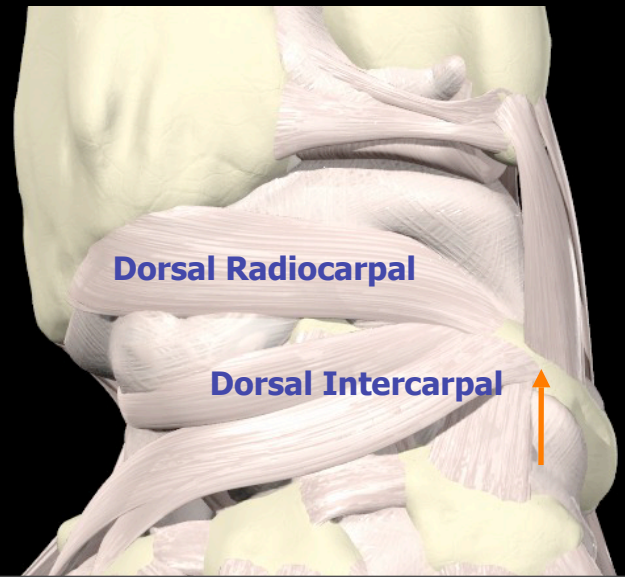
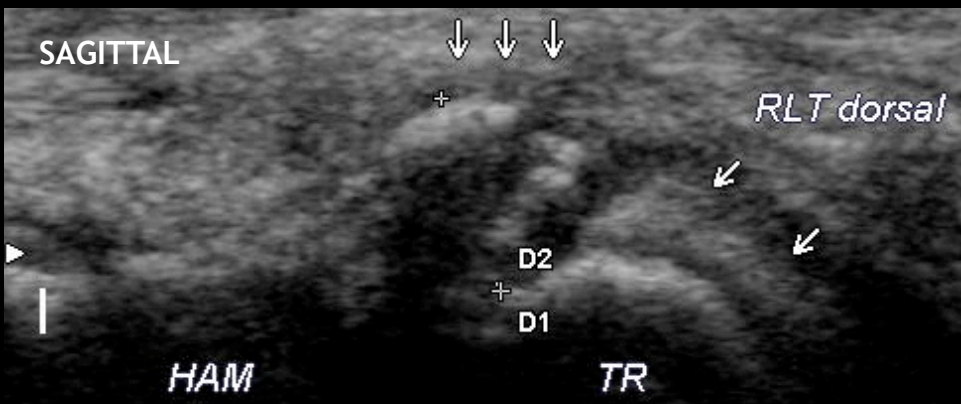DORSAL EXTRINSIC LIGAMENT TEARS

- Isolated or associated with scapholunate ligament tears
- Triquetral attachment is mostly involved.



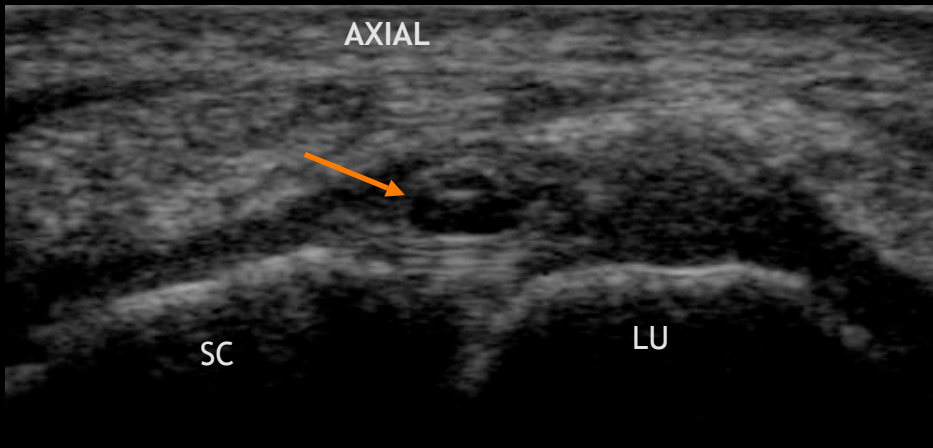
X-rays confirm dorsal cortical avulsion of the triquetrum.

US shows cortical avulsion of the triquetrum at the insertion of the dorsal scaphotriquetral ligament (main component of the dorsal intercarpal ligament).

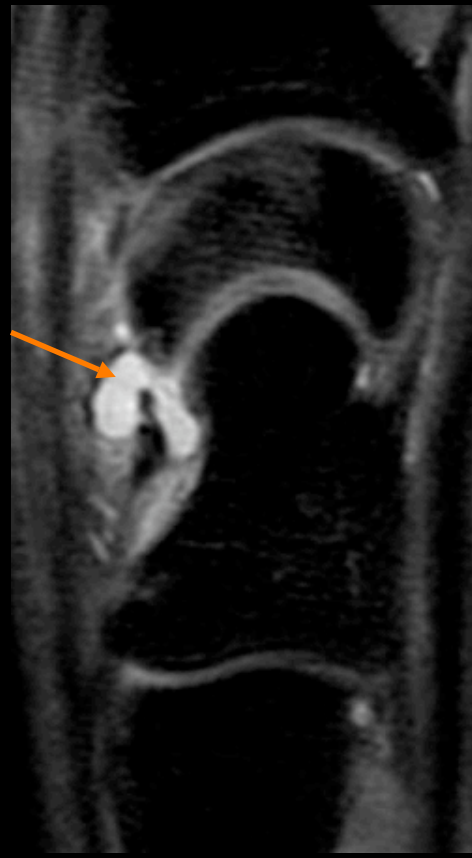
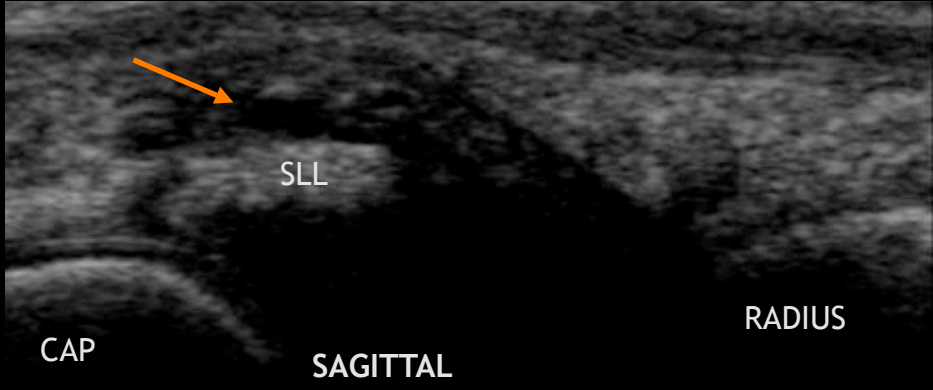


DORSAL OCCULT WRIST GANGLION

- Most common soft tissue mass in wrist
- Small, painful and not palpable ganglion
- Superficial to scapholunate ligament
- Pain may be explained by the close relationship between scapholunate ligament and the terminal branch of posterior interosseous nerve.



Ultrasonography shows anechoic dorsal ganglion cyst located over dorsal component of scapholunate ligament.



Sagittal FS PD FSE MR shows homogeneous hyperintense soft tissue cystic mass.

DISCUSSION: Strengths

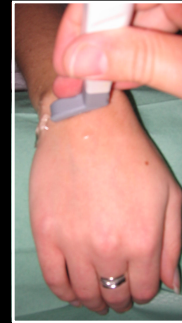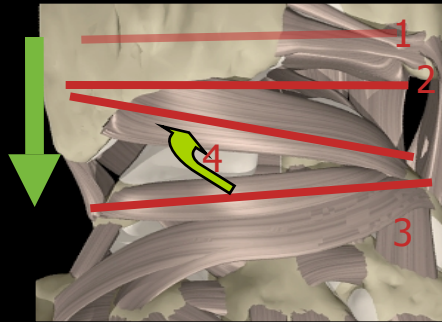
- Advantages of ultrasonography: widely available, low-cost and non-invasive technique.
- Normal analysis: the dorsal portion is the most important structure to identify and its visualization is almost constant according to recent studies.
- Pathologic aspects: easy to classify as any ligamentous tear.
- Differential diagnosis: ultrasonography is sufficient to diagnose dorsal wrist ganglion and De Quervain's tenosynovitis. Its role is demonstrated for diagnosis of occult wrist fractures.
- Scapholunate instability: ultrasonography is another useful tool which can verify integrity of the ligament. In case of abnormality, other examinations are required.

DISCUSSION: Weaknesses

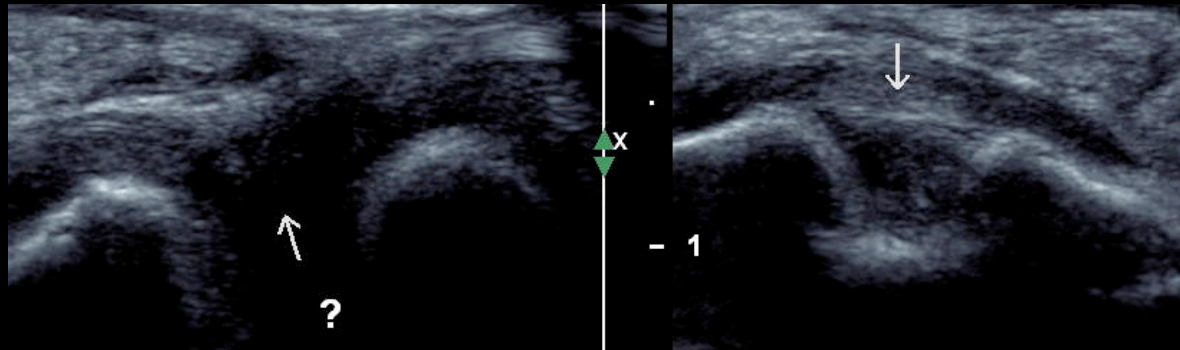
- Limits of ultrasonography: investigator with technical experience and high-frequency probe required.
- Normal analysis: only the dorsal portion of the ligament is easy to identify.
- Pathologic aspects: frequent degenerative changes.
- Scapholunate instability: several ligaments may be involved in wrist instability and have to be explored at the same time.
- Lack of cartilaginous structure analysis leads to limit the use of ultrasonography for acute lesions.

CONCLUSION

- After an acute wrist trauma and in case of normal plain radiographs, scapholunate ligament analysis must be performed by ultrasonography according to a standardized method.



- Despite some limitations, ultrasonography allows to classify ligament injuries (distension, partial or complete tears). The main ultrasonography pattern of scapholunate ligament tear is an anechoic scapholunate gap.



REFERENCES

- [Boutry N, Lapegue F, Masi L, Claret A, Demondion X, Cotten A](#). Ultrasonographic evaluation of normal extrinsic and intrinsic carpal ligaments: preliminary experience. *Skeletal Radiol*. 2005 Sep;34(9):513-21
- [Finlay K, Lee R, Friedman L](#). Ultrasound of intrinsic wrist ligament and triangular fibrocartilage injuries. *Skeletal Radiol*. 2004 Feb;33(2):85-90
- [Dao KD, Solomon DJ, Shin AY, Puckett ML](#). The efficacy of ultrasound in the evaluation of dynamic scapholunate ligamentous instability. *J Bone Joint Surg Am*. 2004 Jul;86-A(7):1473-8.
- [Kendi AT, Gedemez E](#). Sonographic evaluation of scapholunate ligament: value of tissue harmonic imaging. *J Clin Ultrasound*. 2006 Mar-Apr;34(3):109-12.
- [Jacobson JA, Oh E, Propeck T, Jebson PJ, Jamadar DA, Hayes CW](#). Sonography of the scapholunate ligament in four cadaveric wrists: correlation with MR arthrography and anatomy. *AJR Am J Roentgenol*. 2002 Aug;179(2):523-7



Centre d'imagerie ostéo-articulaire
Clinique du sport de Mérignac

www.image-echographie.net

contact: lionelpesquer@gmail.com